



CVJ AFRICA

www.cvja.co.za

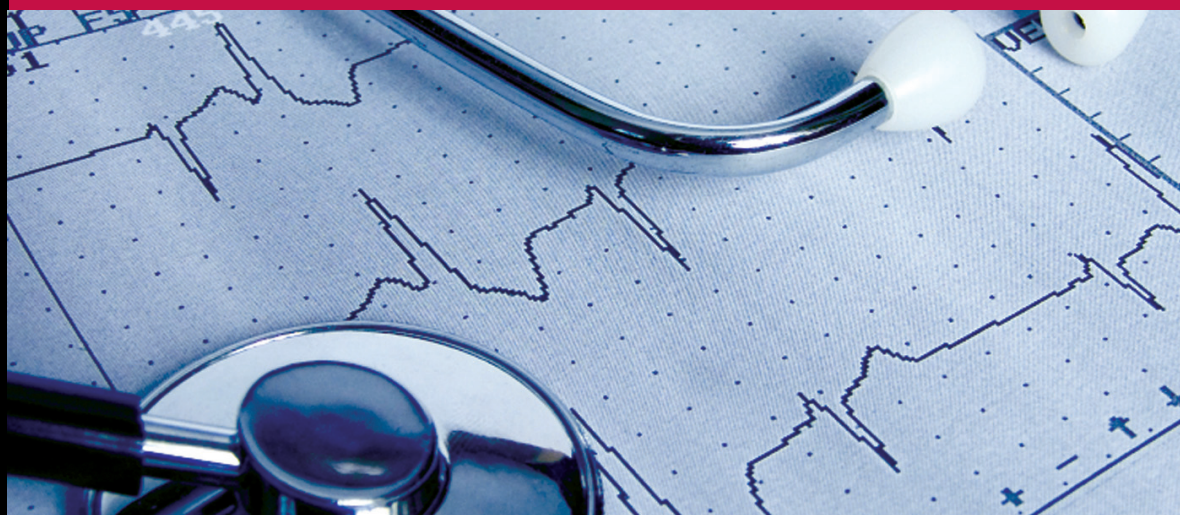CardioVascular Journal of Africa (official journal for PASCAR)



The Panafrican Course on Interventional Cardiology

17-19 December 2020

Virtual Edition



Dear friends and colleagues

The **21st edition of PAFCIC** was supposed to take place on October 2020 in Marrakech (Morocco) jointly with the annual congress of the Moroccan Society of Cardiology. However, because of the COVID-19 outbreak, the meeting was canceled and in exchange will be exceptionally organized as a unique **DIGITAL LIVE** experience with a highly interactional program.

As for the previous years, **PAFCIC** will be organized under the auspices of The Tunisian Society of Cardiology and Cardiovascular Surgery (STCCCV) and The Panafrican Society of Cardiology (PASCAR) with the contribution of the working groups on interventional cardiology of the African national societies such as GTCI, AGIC and others. PASCAR the new born association of structural and cardiovascular intervention of PASCAR will be heavily involved.

The program will be case learning based with several live transmission from the four corners of the globe.

There will be also, practical workshops, live in a box sessions, dedicated sessions for cath lab technicians and CCU nurses as well as keynote lectures by renowned speakers. Africa Fellows Summit will be organized for the seventh year in a row, jointly with **PAFCIC** and will comprise an exciting program dedicated to the young generation.


So we are excited and delighted to have you join us virtually this year to share together knowledge and experience in a friendly environment.



Pr Mohamed Ben Farhat



Pr Habib Gamra



Pr Horst Sievert

Disclaimer

The Abstracts for the PAFCIC 2020 was reviewed by the PASCAR Interventional Task Team and not by the Editor-in-Chief, Regional Editors or reviewers of the *Cardiovascular Journal of Africa*. Only accepted and presented abstracts are published.

Under The Patronage of
The Minister of Health of the Republic of Tunisia

**Twenty First PANAFRICAN COURSE ON
INTERVENTIONAL CARDIOLOGY**



17-19 December 2020

Virtual Edition



STCCCV



PAFCIC Board:

Founding President:	Mohamed Ben Farhat
Course Chairman:	Habib Gamra
Course Directors:	Mohamed Ben Farhat Habib Gamra Horst Sievert
Course Co-Directors:	Kais Battikh Fethi Betbout Alain Cribier Jean Fajadet Mohamed Jeilan Harun Otieno Augusto Pichard Fehmi Remadi Patrick Serruys Mohamed Sobhy Ahmed Suliman

Scientific Board:

Habib Gamra, Tunisia
Horst Sievert, Germany
Kamal Chitkara, United Kingdom
Mohamed Jeilan, Kenya
Awad Mohamed, Sudan
Emmy Okello, Uganda
Harun Otieno, Kenya
Ahmed Suliman, Sudan
Kais Battikh, Tunisia
Samir Ahnia, Algeria
Mpiko Ntsekhe, South Africa
Nadia Fellat, Morocco
Edoardo Camenzind, France
Jonathan Byrne, United Kingdom
Salim Ben Khedda, Algeria
Mohamed Sobhy, Egypt
Adel Bouraghda, Algeria
Jean Fajadet, France
Patrick Serruys, The Netherlands
Fethi Betbout, Tunisia
Fehmi Remadi, Tunisia
Alain Cribier, France
Augusto Pichard, USA

Live Transmission Sites:

- Fattouma Bourguiba University Hospital, Monastir, Tunisia
- International Medical Center, Jeddah – Kingdom of Saudi Arabia
- Cedars Sinai Medical Center – Los Angeles, USA
- Sunninghill Hospital, Johannesburg, South Africa
- Kings College Hospital, London, United Kingdom
- Netcare Union Hospital, Alberton, South Africa
- Karolinska Institute, Stockholm, Sweden
- La Rabta Hospital, Tunis, Tunisia
- Shaab University hospital, Khartoum, Sudan
- International Cardiology Center, Alexandria, Egypt

Live Transmission Sites:

<http://eventek-tn.com/PAFCIC2020>

CLICK HERE FOR LINK TO JOIN THE SESSIONS

Thursday December 17th 2020

In Association with Africa Fellows Summit Learning from challenging cases

10:30 – 12:00

Learning From Challenging Cases Adult CV Interventions

Main Hall

Chairs: Habib Gamra – Abdallah Mahdhaoui – Semi Mourali – Ibrahim Touré – Abdelhadi Kadidi – Selim Ben Khedda

Q&A Moderator: Khaldoun Ben Hamda

Case 1: Complex Left main PCI

Slim Boudiche, Tunisia

Case 2: STEMI management in the COVID-19 era

Wathik Takdemet, Algeria

Case 3: Unexpected hemodynamic instability during PCI

Roland Nguetta, Cote d'Ivoire

Case 4: PCI in a high bleeding risk patient

Samir Ztot, Morocco

12:15 – 13:45

Learning From Challenging Cases Pediatric CV Interventions

Main Hall

Chairs: Shakeel Qureshi – Fekria Abid - Fatma Ouarda – Nadia Fellat – Faouzi Maatouk

Q&A Moderator: Dorra Abid

Case 1: Challenging coarctation case

Shakeel Qureshi, UK

Case 2: Sapien Pulmonary valve implantation guided by 3d printed model simulation

Mario Carminati, Italy

Case 3: Aortic coarctation and what else?

Elyes Neffati, Tunisia

Case 4: PDA closure in premature neonates

Alain Fraisse, UK

Case 5: Challenges on PDA percutaneous closure Cameroon

Jean Claude Ambassa, Cameroon

Case 6: When the RV is between a stenosed pulmonar valve and A LAD fistula, how to treat?

Essia Boughezala, Tunisia

[CLICK HERE FOR LINK TO JOIN THE SESSIONS](#)

Thursday December 17th 2020

In Association with Africa Fellows Summit Complex PCI

Official Opening Ceremony

14:00 – 15:30

Chairs: Mohamed Ben Farhat- Saad Subahi – Lilia Zakhama –
Leila Abid – Lotfi Slimene – Rachid Boujenah – Edoardo Camenzind

Q&A Moderator: mmy Okello

Welcome words: His excellence The Minister of Health of
The Republic of Tunisia

Faouzi Mehdi, Tunisia

Welcome words: Tribute to Professor Mohamed Guediche:
Honorary President of PAFCIC

Mohamed Ben Farhat, Tunisia

Introduction – session objectives

Habib Gamra, Tunisia

Defining the strategy of a CTO

PCI Khaldoun Alaswad, USA

Guidewire selection

Marouane Boukhris, Canada

Microcatheters and balloons

Michel Pansieri, France

Guide extension

Mohamed Jeilan, Kenya

Simplified retrograde approach for CTO PCI

Ahmed El Guindy, Egypt

Live from Alberton – South Africa

CTO PCI: Step by step

Sponsored by ASAHI



15:30 – 16:30

A case of antegrade/ retrograde approach

Operator: Chris Zambakides

Main Hall

Chairs: Khalid Tammam – Ahmed El Guindy – Cherif Mboup - Marouane Boukhris –
Zied Ibn El Hadj – Najeh Bem Halima

Q&A Moderator: Mejdi Ben Messaoud

16:30 – 17:00

Virtual Visit of Exhibitions

E Moderated Poster Session 1

Poster Hall A & B

Moderators: Hichem Denguir – Nashwa Abderrahim – Selma Charfeddine – Sami Ouannes

17:00 – 18:30

In Association with Africa Fellows Summit

Left main PCI

Main Hall

Chairs: Rachid Boujenah – Mohamed Sobhy – Mohamed Jeilan – Maboury Diao –
Ahmed Suliman

Q&A Moderator: Rania Hammami

Introduction – session objectives

Ahmed Suliman, Sudan

Why should we continue to do PCI for left main stenosis?

Mohamed Sobhy, Egypt

Safe stenting of left main : Tips and Tricks

Awad Mohamed, Sudan

IVUS, OCT or just fluoro?

Edoardo Camenzind, France

One or two stents?

Adel Bouraghda, Algeria

DK crush, TAP or other technique?

Jamel Langar, Tunisia

Take home message

Mohamed Jeilan, Kenya

19:00 – 19:30

The role of Clopidogrel in 2020
Sponsored by Sanofi

Main Hall

Chairs: Habib Boussadia – Fehmi Remadi – Anissa Joulak – Habib Gamra – Kais Battikh

Q&A Moderator: Majed Hassine

The role of Clopidogrel in 2020

Leila Abid, Tunisia

Friday December 18th 2020

09:00 – 10:30

CSI Africa @ PAFCIC

Main Hall

Chairs: Abdelfattah Abid – Elyes Neffati – Shakeel Qureshi – Fatma Ouarda –
Essia Boughzela – Hela Messaed – Wafa Fehri – Syrine Abid

Q&A Moderator: Kaouther Hakim

Introduction – session objectives

Shakeel Qureshi, UK

Live from La Rabta Hospital – Tunis
VSD closure



Main Hall

Operators: Semi Mourali – Abdeljelil Farhati

Transcatheter closure of VSD: state of the art

Transcatheter Treatment of complex systemic pulmonary Shunts

For which foetal cardiopathy do we intervene and when?

3D medical modeling to improve the management of complex congenital heart disease and structural heart defects.

Take home message

Do Nguyen Tin, Vietnam

Maurizio Marasini, Italy

Sharland Gurleen, United Kingdom

Adam Kolesnik, Poland

Shakeel Qureshi, United Kingdom

10:30 – 11:00

Virtual Visit of Exhibitions
E- Moderated Poster Sessions 2

Poster Hall A & B

Moderators: Mzee Ngunga – Hedi Ben Slima – Faten Triki – Mehdi Boussaada

11:00 – 12:00

New Devices For TAVI
Live from Karolinska Institute –
Stockholm – Sweden



Main Hall

Operator: Nawzad Saleh

Chairs: Alain Cribier – Mohamed Balghith – Horst Sievert – Morshed Marouane – Dhaker Lahidheb – Nadhem Hajlaoui – Mohamed Chettibi

Q&A Moderator: Jonathan Byrne

Keynote Lecture

Main Hall

TAVI in 2020: Are there still unresolved issues?

Alain Cribier, France

12:00 – 13:00

Africa PCR @ PAFIC

**Live transmission from Sunninghill Hospital,
Johannesburg, South Africa**
Paravalvular leak closure



Chairs: Ahmed Suliman – Mohamed Sobhy – Imed Frikha – Yemi Johnson – David Kettles
– Sondos Kraiem – Soraya Ben Youssef – Robert Mvungi

Q&A Moderator: Kais Battikh

Introduction – session objectives

Live transmission from Johannesburg Operator:

Update:

- How do I manage patients with paravalvular leak?
- How do I close percutaneously paravalvular leak?

Take home message

Mohamed Jeilan, Kenya

Farrel Hellig

Jonathan Byrne, UK

Horst Sievert, Germany

David Kettles, South Africa

13:00 – 13:30

Live From Osaka, Japan
Sponsored by Terumo



Main Hall

Chairs: Habib Gamra – Riyadh Kasri – Helmi Kammoun – Fahd Chaara – Mohamed Hmem

Q&A Moderator: Habib Ben Ahmed

How do I manage complications in the cath lab?

Shozo Ishihara, Japan

13:30 – 14:45

Innovations Session
Techniques You Have Never Seen Before

Main Hall

Chairs: Jamel Langar – Stephen Lee – Khelil Hamza – Shakeel Qureshi –
Abdallah Shehab – Hany Ragy

Q&A Moderator: Kais Battikh

Radio Frequency wire based transeptal catheterization

Unusual access to the heart: transhepatic approach

Current tools for mesenteric ischemia intervention

Dealing with severe pulmonary regurgitation and
pseudoaneurysm of RVOT by catheter methods

New tools for transcatheter therapy of chronic
venous insufficiency

Catheter based management of coronary aneurysm

Stefan Bertog, Germany

Mario Carminati, Italy

Max Amor, France

Shakeel Qureshi, UK

Romarc Loffroy, France

Farrel Hellig, South Africa

14:45 – 15:30

**Live Transmission from Kings College,
London, UK**
Coronary sinus reducer



Main Hall

Chairs: Yemi Johnson – Assad Chaara – Kais Battikh – Ahmed Magdy – Zied Ibn Elhadj –
Cherif Abdelkhirane – Majed Hassine

Q&A Moderator: Samir Ahnia

Coronary sinus reducer: Current evidence

Jonathan Byrne, UK

CLICK HERE FOR LINK TO JOIN THE SESSIONS

Friday December 18th 2020

14:00 – 16:00

Allied Professionals Session

Hall C

Chairs: Fethi Betbout – Gouider Jeridi – Habib Ben Ahmed – Hassine Guedria – Abdellateef MA Abdelrahem

What do you need to know about CTO PCI?

Primary PCI

Preparation of a rotablator procedure

Working in the cath lab in the COVID-19 era

Mejdi Ben Messaoud, Tunisia

Slim Boudiche, Tunisia

Kamel Ben Nasr, Tunisia

Nashwa Abderrahim, Sudan

15:30– 16:30

Live from International Medical Center – Jeddah Complex CTO PCI Sponsored by ASAHI



Main Hall

Chairs: Fehmi Remadi – Hadi Abu Hantash – Khaldoun Ben Hamda – Khaldoun Alaswad – Omer Goktekin

Q&A Moderator: Marouane Boukhris

Operator: Khalid Tammam

The ten commandments of CTO PCI

Khaldoun Alaswad, USA

16:30 – 17:00

Virtual Visit of Exhibitions E-Moderated Poster Session 3

Poster Hall A & B

Moderators: Mejdi Ben Messaoud, Marouane Mahjoub, Meriem Drissa, Ayman Hraiech

17:00 – 18:00

Live transmission from International Cardiac Center, Alexandria – Egypt PCI of a complex bifurcation



Chairs: Adel Etriby – Faouzi Drissi – Ziyad Ghazzal – Wissem Sdiri – Skander Ben Omrane – Fahd Chaara – Najeh Ben Halima

Q&A Moderator: Nazim Maghrebi

A case of complex coronary bifurcation

Operators: Mohamed Sobhy

Mohamed Sadaka

Moustafa Elwany

Awad Mohamed, Sudan

How to perform a safe PCI of a complex coronary bifurcation?

18:00 – 19:00

Live transmission from Cedars Sinai MC Los Angeles – USA Percutaneous tricuspid / mitral valve repair



Main Hall

Chairs: Horst Sievert – Nadhem Hajlaoui – Habib Gamra – Faouzi Addad – Bernard Gersh – Michel Pansieri – Abdoul Kane

Q&A Moderator: Leila Hached

Introduction – session objectives.

Percutaneous tricuspid Valve replacement

& mitral valve repair

Horst Sievert, Germany

Operator: Raj Makkar (LA, USA)

Friday December 18th 2020

19:00 – 19:30

Keynote Lecture

Chairs: David Kettles – Mohamed Jeilan – Habib Gamra
Long term cardio-vascular complications in COVID survivors:
Knowns & Unknowns

Bernard Gersh, USA

19:30

NOAC's in routine clinical practice Sponsored by Teriak

Main Hall

Habib Gamra, Tunisia

Chairs: Sami Mourali – Faouzi Addad – Helmi Kammoun
Q&A Moderator: Faten Triki

Saturday December 19th 2020

09:00 – 10:30

Structural Interventions in Africa

Main Hall

Chairs: Shakeel Qureshi – Mario Carminati – Rachid Mechmeche - Fethi Betbout –
Osama Rifaie – Amine Jemel – Salim Bem Khedda – Reuben Mutagaywa

Q&A Moderator: Emmy Okello

Introduction – session objectives

Shakeel Qureshi, UK

Live transmission from Shaab University Hospital Khartoum, Sudan Balloon Mitral Valvuloplasty during pregnancy



Operator: Ahmed Suliman

How to perform a safe transseptal puncture?
Balloon mitral valvuloplasty: State of the art

Nesma Ben Dagha, Morocco
Habib Gamra, Tunisia

10:30 – 11:00

Virtual Visit of Exhibitions E-Moderated Poster Session 4

Poster Hall A & B

Moderators: Mehdi Slim, Semi Milouchi, Abraha Hailu, Nidhal Bouchahda

[CLICK HERE FOR LINK TO JOIN THE SESSIONS](#)

Saturday December 19th 2020

10:00 – 12:00

**Live transmission from Fattouma Bourguiba
University Hospital**
Septal Ablation for Obstructive Cardiomyopathy



Main Hall

With Remote proctoring by Hubert Seggewiss (Germany)

Chairs: Abdallah Mahdhaoui – Sami Mourali – Salem Abdessalem – Awad Mohamed –
Habib Boussadia – Habib Ben Ahmed – Dhaker Lahidheb

Q&A Moderator: Omar Ait Mokhtar

Operators: Fethi Betbout & Habib Gamra

Recent developments in septal ablation for
obstructive cardiomyopathy

Hubert Seggewiss (Germany)

11:00 – 13:00

Implantable Cardioverter Defibrillators State of the art
Sponsored by Boston Scientific

Hall C

Chairs: Sonia Chabrak – Youssef Ben Ameer – Aymen Hraiech – Majed Hassine

Q&A Moderator: Sana Ouali

Optimal programming of ICDs in primary and secondary
prevention: what to do to avoid unnecessary shocks?

Subcutaneous ICD: advantages, disadvantages, indications
and prospects

Is there still a place for defibrillation in primary prevention in
the era of new therapies for heart failure?

CRT Experience sharing – Challenging cases

CRT Best Practices – Optimization for HF patients

Strengths of Boston Scientific's Discrimination Algorithms.

New developments in cardiac pacing and defibrillation

Salma Krichene, Tunisia

Abdeddayem Haggui, Tunisia

Emna Allouch, Tunisia

Bernard Harbieh, Lebanon

Najmeddine Echahidi, France

Olivier Bazillais, France

12:30 – 14:00

**Complications From The Masters Under The Auspices of
GTCI – AGIC – PASCI - CardioAlex**

Main Hall

The case I have most learned from in my career

Chairs: Eric Eeckhout – Antonio Colombo – Kamal Chitkara – David Kettles – Mohamed Sobhy

Q&A Moderator: Habib Gamra

Expect the unexpected

Lessons learned from one patient over 30 years

Catch me if you can

Make the correct diagnosis before treatment

Coronary perforation

A memorable paravalvular leak closure

Too much good could lead you to bad

An extremely tough retrograde CTO recanalization –

The application of ESC principle

Eric Eeckhout, Switzerland

Farrel Hellig, South Africa

Kamal Chitkara, United Kingdom

Antonio Colombo, Italy

Antonio Colombo, Italy

Horst Sievert, Germany

Max Amor, France

Bin Zhang, China

[CLICK HERE FOR LINK TO JOIN THE SESSIONS](#)

Saturday December 19th 2020

14:30 – 15:00

Closing Keynote Lecture

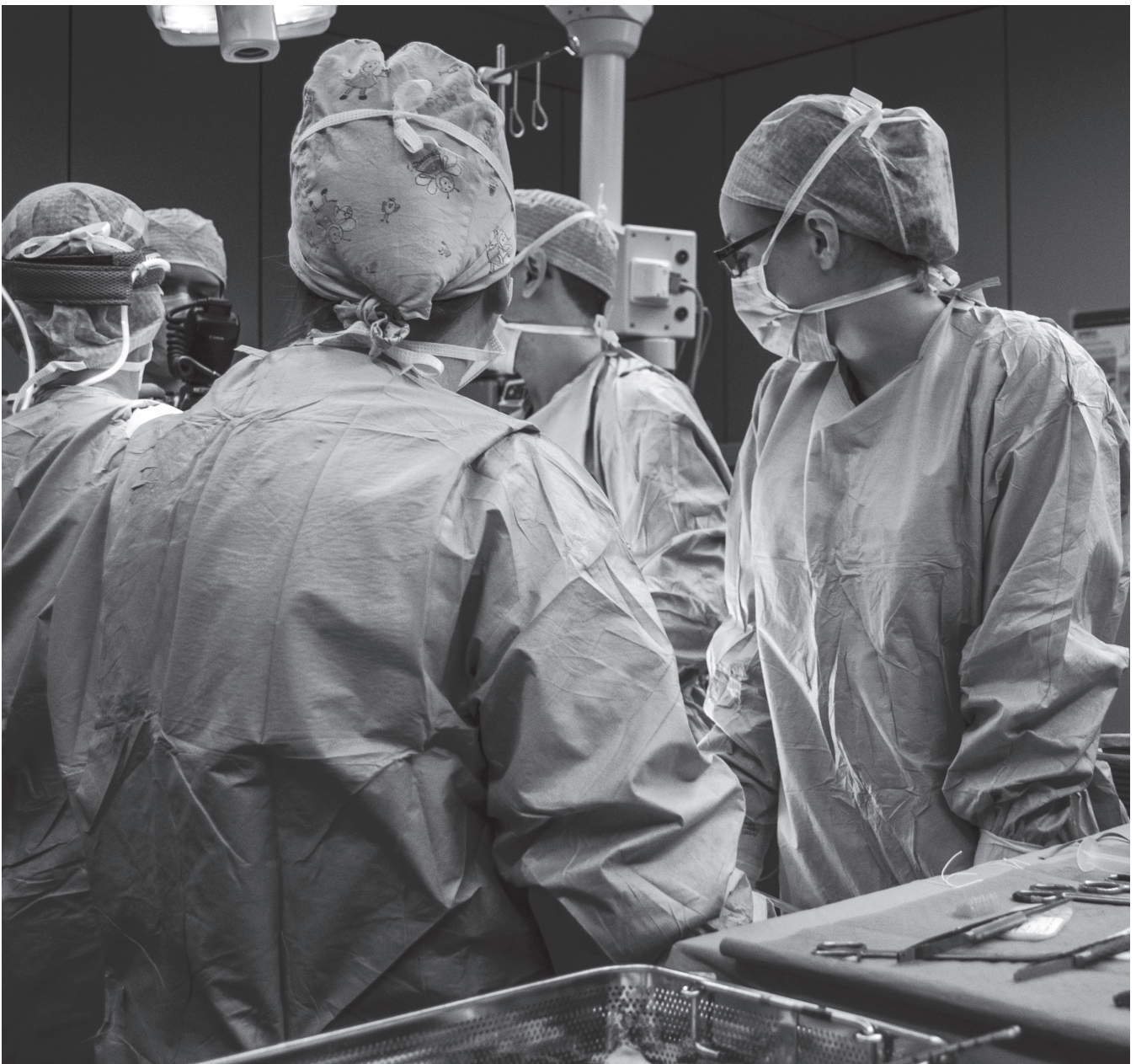Main Hall

Chairs: Mohamed Ben Farhat – Horst Sievert – Habib Gamra
Artificial intelligence in cardiology

Thierry Corcos, France

Closing Remarks / Meeting Highlights

Mohamed Ben Farhat – Habib Gamra – Horst Sievert



Entry ID	Name	Surname	English Title	Session	Email
565	YAAKOUBI	WAEL	A rare cause of Familial atrioventricular block with a novel LMNA mutation (p. Ala502Val)	SESSION 1 HALL A 17 December 2020 : 04h00 – 04h30 PM	yaakoubiwael3@gmail.com
607	Mohamed	Aouina	Review of 76 cases of infective endocarditis : A Tunisian Cohort		mohaamed91aouina@gmail.com
571	YAAKOUBI	WAEL	ST-elevation Myocardial Infarction in Anomalous Origin of Right Coronary Artery From the Left Sinus of Valsalva and Interarterial Course : a case report.		yaakoubiwael3@gmail.com
577	Mohamed Aymen	Ben Abdessalem	Drug eluting balloons versus drug eluting stents to treat in stent restenosis: a monocentric observational study		aymen.abdessalem@aol.com
581	Sabrine	Soudani	The using of 64-slice computed tomography in detection of coronary artery disease in Patients with left bundle branch block		drissameriem@yahoo.fr
579	Ikram	CHAMTOURI	Impact of prehospital delay time on mortality in women with ST-elevation myocardial infarctions		ikram_chamtouri@hotmail.fr
605	TAAMALLAH	Karima	Localization of coronary artery stenoses in patients with coronary artery disease: Role of speckle tracking imaging		cardiokarima@yahoo.fr
576	Houaida	Mahfoudhi	Subclinical detection of myocardial impairment in rheumatoid arthritis		mahfoudhihouaida@yahoo.fr

Entry ID	Name	Surname	English Title	Session	Email
602	ATAOUI	Sawssen	Estimation of Left Ventricular Filling Pressure in Patients with Ischemic Cardiomyopathy : Role of Left atrial strain	SESSION 1 HALL B 17 December 2020 : 04h00 – 04h30 PM	cardiokarima@yahoo.fr
604	Housseem	Thabet	Iatrogenic myocardial perforation		housseem2.thabet@gmail.com
582	bouraoui	hatem	Impact of diabetes on long term prognosis of patient with STEMI treated with Primary PCI.		hatembouraoui@yahoo.fr
583	bouraoui	hatem	Delay to reperfusion in STEMI: Gaps between recommendation and real word.		hatembouraoui@yahoo.fr
584	BEN MRAD	Melek	Femoropopliteal Angioplasty: Short and Mid-Term Results: Results of a Cohort of 289 Cases		benmradmelek@gmail.com
585	BEN MRAD	Melek	Mechanical Thrombectomy in Acute Thrombosis of Dialysis Arteriovenous Fistulae : report on the experience of a Tunisian center		benmradmelek@gmail.com

Entry ID	Name	Surname	English Title	Session	Email
614	Housseem	Thabet	We did everything, but....	SESSION 2 HALL A 18 December 2020 : 11h00 – 11H30 AM	housseem2.thabet@gmail.com
566	YAAKOUBI	Wael	NEW-ONSET ATRIAL FIBRILLATION AFTER ACUTE CORONARY SYNDROME: PREVALENCE, PREDICTIVE FACTORS AND PROGNOSIS		yaakoubiwael3@gmail.com
755	Houaida	Mahfoudhi	Real time-2D and 3D transesophageal echocardiography assessment of atrial septal defects		mahfoudhihouaida@yahoo.fr
574	Houaida	Mahfoudhi	Benefits of measuring maximum myocardial oxygen consumption in children with congenital heart disease		mahfoudhihouaida@yahoo.fr
612	Anouar	Yassine	Left Ventricular Rapid Pacing in TAVI		y.anouar.y@gmail.com
608-9	Amani	Maatouk	Analysis of the performance of the EuroSCORE II according to the calibration approach in a Tunisian population		amani.maatoukk@gmail.com

Entry ID	Name	Surname	English Title	Session	Email
629	Rekik	Bassem	PROGNOSTIC VALUE OF PREOPERATIVE HIGHLY-SENSITIVE TROPONIN IN PREECLAMPSIA	SESSION 2 HALL B 18 December 2020 : 011h00 – 11H30 AM	bassem.rekik@yahoo.fr
627	Ikram	CHAMTOURI	Six-year follow up of left atrial appendage closure with Watchman device		ikram_chamtouri@hotmail.fr
730	Housseem	Thabet	Correlation between the severity of cirrhosis and electro-echocardiographic parameters		housseem2.thabet@gmail.com
625	Soudani	Sabrine	Characteristics of acute coronary syndrome without ST segment elevation in elderly		drissameriem@yahoo.fr
623	Chenik	sarra	Ventricular Diastolic Dysfunction in Sickle Cell Anemia		cheniksarra@gmail.com
624	ben mrad	melek	Percutaneous transluminal stenting of the common carotid artery in nonspecific aortoarteritis: a case report		benmradmelek@gmail.com
630	ben mrad	melek	Subintimal Recanalization of an Occluded Common Iliac Stent: A Case Report		benmradmelek@gmail.com

Entry ID	Name	Surname	English Title	Session	Email
654	zeineb	oumaya	Arterial thrombosis in a patient with Coronavirus Disease	SESSION 3 HALL A 18 December 2020 : 04h15 – 04H45 PM	oumayazeineb1992@gmail.com
674	sobhi	mleyhi	The E-vita Open Plus prothesis in the aortic arch and descending aorta surgery: first case in Tunisia.		mleyhisobhi@yahoo.com
671	Saeb	Ben Saad	Percutaneous coronary intervention with bare metal stents in the age of drug eluting stents; assessment of practices and results in terms of in-stent restenosis		saeb.ben.saad.md@gmail.com
653	Asma	Brahim	Could P wave peak time predict the severity of coronary artery disease in patients with non-ST segment elevation myocardial infarction?		dr.allouche.emna@gmail.com talhaouiamira@gmail.com
657	Mariam	Madiouni	Catastrophic embolic complications in a patient with left ventricular non-compaction		dr.allouche.emna@gmail.com madiounimariam@outlook.fr
666	BOUDICHE	SELIM	Percutaneous coronary intervention with rotational atherectomy: immediate and long-term results.		selim.boudiche@gmail.com
648	ben mrad	melek	Percutaneous angioplasty of the Profunda femoris artery: a safe and effective endovascular technique		benmradmelek@gmail.com

Entry ID	Name	Surname	English Title	Session	Email
681	Triki	Zied	Predictors of mortality and rehospitalization in acute coronary syndromes with left bundle branch block	SESSION 3 HALL B 18 December 2020 : 04h15 – 04H45 PM	zied.triki@medecinesfax.org
698	Sobhi	Mleyhi	In-hospital mortality predictors of surgical treatment of infective endocarditis		mleyhisobhi@yahoo.com
732	Houssem	Thabet	A comparative study: Postoperative results of Blalock Taussig shunts according to the underlying heart disease and the age of the child.		houssem2.thabet@gmail.com
689	Lagha	Elyes	Acute ST-segment elevation myocardial infarction and cardiac arrest as first clinical manifestation of essential thrombocythemia		laghaelyes93@gmail.com
692	Dardouri	safa	Athlete's heart : endurance versus resistance exercise training		dardourisafa92@gmail.com
693	Dardouri	safa	Cor triatriatum Sinistrum with sinus venosus atrial septal defect and Partial anomalous pulmonary venous return In a newborn : About one case		dardourisafa92@gmail.com
702	BOUSNINA	MOUNA	OXYGEN DELIVERY MONITORING UNDER CARDIOPULMONARY BYPASS: WHAT IMPLICATION ON POSTOPERATIVE MORBIDITY AND MORTALITY?		bousnina.mouna@gmail.com

Entry ID	Name	Surname	English Title	Session	Email
728	Sendi	Tarek	Post-operative morbi-mortality of surgical myocardial revascularization with a single dose of warm blood cardioplegia	SESSION 4 HALL A 19 DECEMBER 2020 : 10h30 – 11H00 AM	tareksendi4@gmail.com
721	MAALEJ	JIHEN	MYOCARDIAL REVASCULARIZATION SURGERY AFTER PERCUTANEOUS CORONARY DILATION: RESULTS OF A TUNISIAN BICENTRIC STUDY		jjhen.maalej@hotmail.fr
729	Housseem	Thabet	Prognostic factors of mediastinitis, single-center study of 39 cases and review of the literature.		housseem2.thabet@gmail.com
569	YAAKOUBI	Wael	Diabetic and nondiabetic patients with acute coronary syndrome: What about the differences?		yaakoubiwael3@gmail.com
742	Emna	Bennour	Subclinical systolic dysfunction in breast cancer patients		bennour_emna@yahoo.fr
740	Soudani	Sabrina	is the profile of Native infective endocarditis changed last ten years ?		soudanisabrina4@gmail.com
724	Talhaoui	Amira	Factors prolonging Hospital Length of Stay in patients with acute coronary syndrome		talhaouiamira@gmail.com
738	Ahmed	SGHAIER	How to manage patients on vitamin K antagonists in the COVID-19 era		sghahmed991@gmail.com
727	Adel	Mrad	Contribution of the cardiac computed tomography in the exploration of mechanical valve prosthesis		adelmrad36@gmail.com

Entry ID	Name	Surname	English Title	Session	Email
744	Tesnim	Besbes	Urgent surgical removal of a ruptured intracardiac cyst mimicking a septal cardiac tumor with neurological symptoms	SESSION 4 HALL B 19 DECEMBER 2020 : 10h30 – 11H00 AM	tesnim.besbes@gmail.com
757	Rahma	Karmous	Role of multimodality imaging in the assessment of prosthetic heart valve obstruction		rahma.karmous@gmail.com
747	Mohamed Aymen	Ben Abdessalem	Should we always crush?		aymen.abdessalem@aol.com
752	Mohamed Aymen	Ben Abdessalem	Ostial RCA In-Stent Restenosis and anomalous left main originating from the right coronary cusp treated with Szabo Technique		aymen.abdessalem@aol.com
748	Kharrat	Sana	FULMINANT MYOCARDITIS IN A PATIENT WITH SEVERE ACUTE RESPIRATORY SYNDROME CORONAVIRUS 2		sanakharrat15@hotmail.com
758	Kharrat	Sana	Severe scorpion envenomation in children and cardiovascular tropism		sanakharrat15@hotmail.com
753	Houaida	Mahfoudhi	Analysis of right ventricular function by 2D speckle imaging in patients with acute myocardial infarction		mahfoudhihouaida@yahoo.fr
743	Aloui	Wafa	Challenging Endovascular Treatment of Thrombosed Arteriovenous Dialysis Fistula		wafaaloui@hotmail.com

Submission ID: 565

A RARE CAUSE OF FAMILIAL ATRIOVENTRICULAR BLOCK WITH A NOVEL LMNA MUTATION (P. ALA502VAL)

YAAKOUBI WAEL, Drissa Mariem, Helali Sana, Cerif Nour, Sta Marouen, Krouf Mohamed Amine, Mrad Ridha, Kyndt Florence, Drissa Hbibha
RABTA Hospital / Charle Nicolle Hospital Tunisia / Nante Teaching Hospital, France

Background:

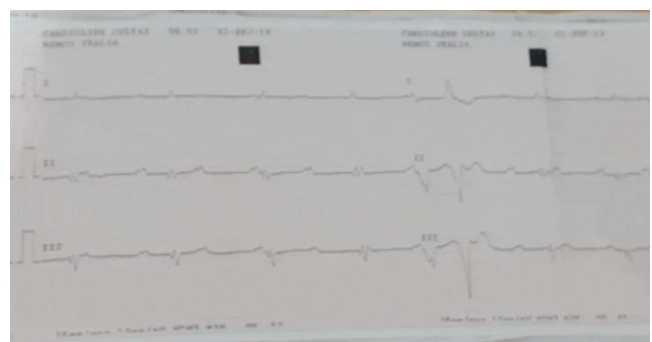
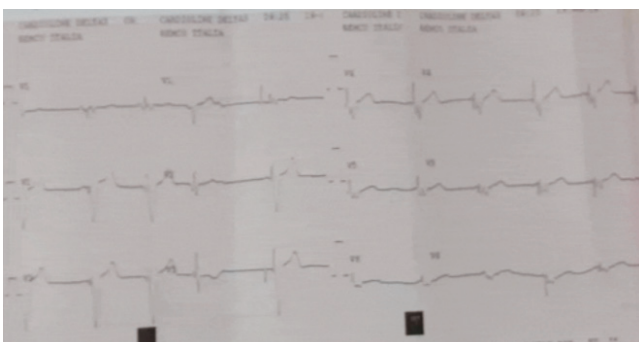
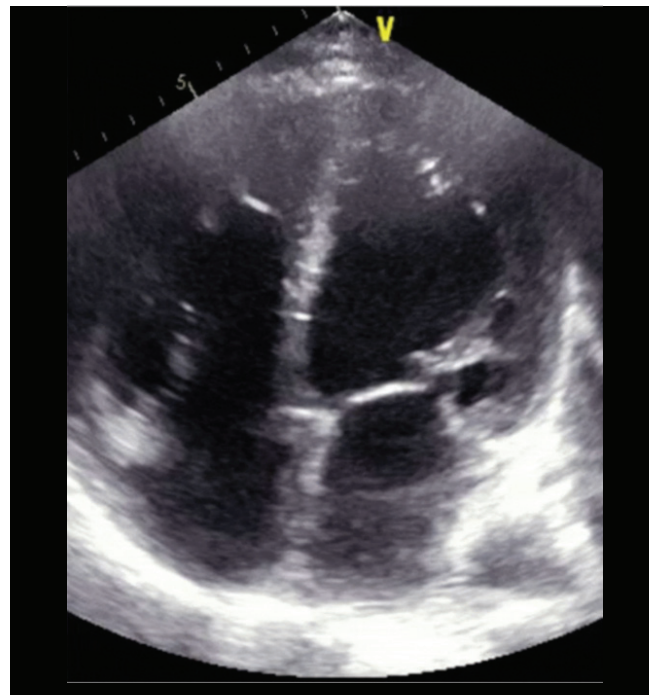
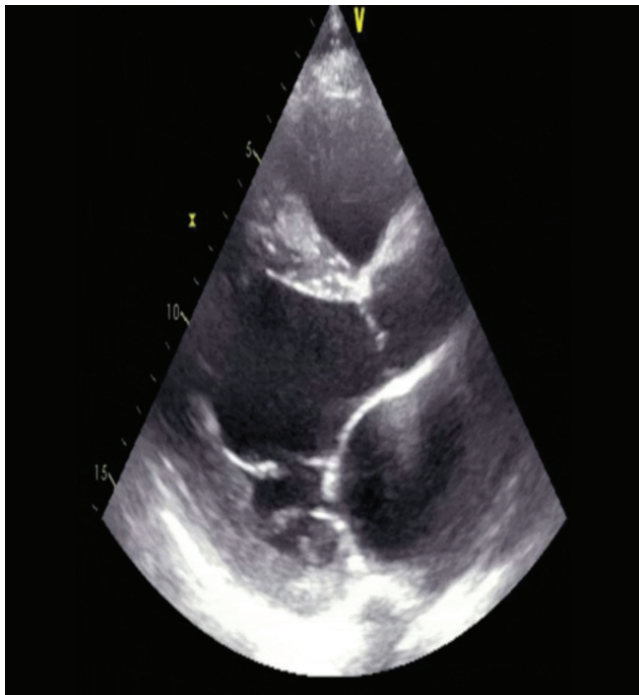
LMNA gene mutations are one of the most frequent genetic abnormalities involved in dilated cardiomyopathy (DCM) and it has been estimated that LMNA mutations cause up to 10% of familial DCM. LMNA mutations are associated with cardiac abnormalities characterized by arrhythmias: sinus node dysfunction, atrioventricular block (AVB), atrial and ventricular arrhythmias.

Case presentation:

A 44-year-old man presented in clinic with dyspnoea dizziness and orthopnoea for 2 weeks. He denied chest pain or fever. His past medical history was unremarkable, without skeletal muscle disease, premature ageing, or metabolic disorders. In his family history we found that: His mother had a complete AVB at age of 50 years treated by double chamber pacemaker, his brother had complete AVB at age of 45 years treated by double chamber pacemaker, his sister had Mobitz I AVB at age of 45 years not yet stimulated, his Maternal uncle had complete AVB at early age treated by double chamber pacemaker, his Maternal Grandmother had complete AVB at age of 50 years treated by double chamber pacemaker. On examination, pulse rate was of 35 beats/min, blood pressure of 100/60 mm Hg. There was no sign of heart failure. The ECG revealed sinus rhythm with 2:1 atrioventricular block (AVB) alternating with complete AVB. Transthoracic Echocardiogram showed dilated left ventricle with ejection fraction estimated at 15% and global hypokinesia. The right ventricle was also dilated. Coronary artery CT angiography showed no abnormality in origin, course, or atherosclerotic change. We decided to implant a triple chamber pacemaker and performed genetic testing using the TruSight Cardio Panel (Illumina, Sophia Genetics), which includes 109 genes. All associated mutations/variants were confirmed by direct Sanger sequencing. A novel LMNA mutation c.1505C>T, g.1561066920C>T (p. Ala502Val) in the LMNA gene was identified. He was discharged after 30 days in relatively good clinical conditions after implantation on standard pharmacological therapy for heart failure. Six months after pacemaker implantation the patient remained asymptomatic. Left ventricular dimension and function were unchanged.

Conclusion:

Our observation illustrates the case of familial AVB associated with DCM which is related to LMNA mutation. Laminopathies are associated with a wide spectrum of disease phenotypes, ranging from skeletal muscle disease, pre-mature ageing, metabolic disorders, and cardiac abnormalities.



Submission ID: 607

REVIEW OF 76 CASES OF INFECTIVE ENDOCARDITIS: A TUNISIAN COHORT

Mohamed Aouina, Marwa Chebbi, Wejdene Ouechtati, Sana Helali, Emna Allouche, Habib Ben Ahmed, Leila Bezdah

Charles Nicolle Hospital of Tunis, Tunisia

Introduction:

Infective endocarditis (IE) remains a challenging disease to manage. The objective of this study is to describe its epidemiological, microbiological and outcome characteristics.

Methods:

This was a descriptive and retrospective study of 76 patients hospitalized and treated for IE in our cardiology department in Charles Nicolle hospital of Tunis, from January 2011 to January 2019.

Results:

76 patients (19-88 years, mean age: 49 years), treated for IE were studied. IE occurred on left heart in 59.2% (n=45) of cases and on right heart in 40.78% (n=31) of cases. Nine cases (11.8%) were prosthetic valve endocarditis. Eleven of patients (14.47%) had chronic renal failure. A history of dental manipulation was observed in 9% of cases. For right sided IE, the predisposing factors were intra-cardiac material (n=6), venous catheter, recent heart surgery, and drug addiction. Transthoracic echocardiography (TTE) and Transoesophageal echocardiography (TEE) were the tool key to identify and describe the vegetation, to quantify the valve regurgitation, to indicate the surgical parameters and to allow a regular follow-up in order to precise the profile of the treatment response. The vegetations were greater than 15 mm in 50 % of cases. Ten patients had annular abscess. Eleven patients had valve perforation. Blood cultures performed for all patients were positive in 48.68% (n= 37) and negative in 51.32% of the population. Staphylococcus was the most frequent responsible microorganism. (51.35%) (n=19). Treatment was given according to international recommendations, based primarily on a bi-bactericidal antibiotic therapy then was adapted to the isolated germ. Early valve surgery was performed in 58.15% (n=44) of patient. The overall in-hospital mortality rate was 21.05% (n=16).

Conclusion:

The epidemiology of infective endocarditis has changed, and the most Causative microorganisms is Staphylococcus. It occurs in relatively young patients. The incidence has increased in patients with intravenous drug abuse and prosthetic heart valves, while it has decreased with rheumatic valvopathy. Treatment of endocarditis includes prolonged antimicrobial therapy and in selected cases, cardiac surgery whose indication is mainly hemodynamic in the left heart IE while it is mainly infectious in the right sided IE.

Submission ID: 571

ST-ELEVATION MYOCARDIAL INFARCTION IN ANOMALOUS ORIGIN OF RIGHT CORONARY ARTERY FROM THE LEFT SINUS OF VALSALVA AND INTERARTERIAL COURSE: A CASE REPORT.

Ben Hlima Manel, Yaakoubi Wael, Boudishe Slim, Mghaith Fathia, Rekik Bassem, Laarbi Nouredine, Farhati Abdejilil, Mourali Med Sami

RABTA Hospital, Tunisia

Background:

Anomalous coronary artery from the opposite sinus (ACAOS) is a rare congenital anomaly. Patient with (ACAOS) can present with symptoms similar to coronary artery disease, and sudden cardiac death. Management of anomalous coronary artery from the opposite sinus varies; however, current guidelines suggest surgery in symptomatic patients.

Case Presentation:

A diabetic and dyslipidemic 45-year-old smoker man who presented to the emergency department with typical chest pain at 60 minutes of

its onset. On examination, he was lying comfortably in bed with a pulse of 100 beats/min regular, blood pressure of 140/85 mm Hg. The electrocardiogram noted an evaluative inferoseptal infarctus with a right ventricle infarctus. The rhythm was sinus. The patient was taken to the catheterization laboratory suite and left heart catheterization with coronary angiography was performed. Imaging revealed a single left sinus of Valsalva ostium that gave rise to the LCA, which divided into the left anterior descending (LAD) and left circumflex arteries. However, there was also an RCA that was originating from the proximal LCA. The RCA did demonstrate a significant stenosis of its second segment. No arteries were found arising from the right coronary cusp. Transthoracic Echocardiogram showed normal size of left ventricle (LVEF was about 60 %), the contractility of the LV was preserved with a mild mitral regurgitation MR. The RV was normal. Speckle tracking (GLS) was about -22%. Coronary computed tomography (CT) angiography scan was performed and demonstrated an interatrial pathway of the RCA as it took a course between the aortic root and pulmonary artery. Based on these images and clinical findings, the decision for percutaneous revascularization was made. A coronary artery PCI was performed with a DES. The patient tolerated the procedure well without complications and was taken to the intensive care unit. He was subsequently discharged but and was awaiting follow-up. A stress test was performed after 03 months of PCI which did not show any sign of ischemia.

Conclusion:

Although ACAOS is fairly rare, the potential risk of sudden cardiac death and other adverse complications make accurate diagnosis and treatment of this condition crucial to maximizing patient outcomes. This case is a good representation of what the current literature recommends in terms of appropriate workup and treatment and serves to add to our growing knowledge of ACAOS and its management.

Submission ID: 577

DRUG ELUTING BALLOONS VERSUS DRUG ELUTING STENTS TO TREAT IN STENT RESTENOSIS: A MONOCENTRIC OBSERVATIONAL STUDY

Mohamed Aymen Ben Abdesslem, Zied Ben Ameer, Hamza Mosrati, Saoudi Wassim, Imen Bouhleb, Hatem Bouraoui, Abdallah Mahdhaoui, Samia Ernez, Gouider Jeridi

Farhat Hached University Hospital Cardiology Dpt. Research Laboratory LR14ES05 University of Sousse.

Introduction:

Despite progress made in drug eluting stents (DES) in the 2 previous decades, in stent restenosis (ISR) remains a frequent complication of coronary angioplasty. Drug Coated Balloons (DCB) are now an established treatment of ISR. Observational data on outcomes of ISR treated with this technique compared to newer generation DES are still scarce.

We aimed to evaluate long term outcomes of patients with ISR treated with paclitaxel coated balloon and compare them to newer generation DES used for the same indication.

Methods:

This is an observational, monocentric, retrospective study evaluating procedural and long-term outcomes of DCB used in the treatment of ISR. Patients in whom ISR was diagnosed and treated whether with DES or DCB were enrolled. A 2.0 µg/mm² paclitaxel coated balloon designed for coronary artery disease was compared to resorbable polymer sirolimus eluting stents, polymer free sirolimus eluting stents and dual therapy resorbable polymer sirolimus eluting stents. Mean follow up period was 24 months. Major cardiovascular event (MACE) is a composite of death from any cause, Target lesion revascularisation (TLR), Target vessel revascularization (TVR), and myocardial infarction (MI).

Results:

68 ISR diagnosed in 62 patients were included. In 24 of the lesions a DCB was used and 44 were treated with DES. The majority 75%

of BMS-ISR was treated with a new DES implantation ($p=0.033$). DCB were used in 58% of DES-ISR ($p=0.043$). Procedural angiographic results evaluated by acute luminal gain (ALG) were similar in the two groups. A median follow-up of 20 months was achieved for 54 patients, 8 were lost to follow-up. Cardiac death wasn't observed in both groups, TVR: 15.7% (3) vs. 14.2% (6) $p=0.54$; TLR 20.9% (4) vs. 23.8% (10) $p=0.57$; MI TVR: 15.7% (3) vs. 14.2% (6) $p=0.58$ and MACE: 26.3% (5) vs. 26.1 % (10) $p=0.9$ in DCB vs. DES groups respectively.

Conclusion:

Long term outcomes of DCB use in ISR in our practice were not different from new DES implantation. This suggests efficacy and safety of DCB compared to newer generation DES.

Submission ID: 581

THE USING OF 64-SLICE COMPUTED TOMOGRAPHY IN DETECTION OF CORONARY ARTERY DISEASE IN PATIENTS WITH LEFT BUNDLE BRANCH BLOCK

amira talhaoui, marouen sta, badr hamzi, sabrine Soudani, syrine dardour, syrine neji, habiba drissa

Introduction:

Left bundle branch block (LBBB) is most commonly associated with atherosclerotic coronary artery disease (CAD). Thus the identification of chronic CAD in patients with LBBB is important to stratify the risk and manage the therapy. Non-invasive stress tests have limited performance, and conventional coronary angiography (CCA) is usually required to confirm diagnosis.

The aim of the present study was to evaluate in a routine clinical practice the diagnostic accuracy of 64-slice CT to identify CAD in patients with complete LBBB compared with CCA.

Method:

A retrospective descriptive study of 90 patients with CAD investigated by 64 slice CT and CCA between the period of 2010 to 2017 then we included only patients with LBBB.

Results:

40 consecutive patients with complete LBBB and sinus rhythm underwent MDCT 4 days before CCA ;they were 18females and 22 males aged from 50 to 73 years, they had one or more than one cardiovascular risks factors.

The indication of MDCT was a chest pain in 33 patients and a left ventricular dysfunction in 7 cases.

The MDCT was normal in 26patients, showed a non-significant coronary stenosis in 5 patients, significant lesion s in 9 cases.

Coronary angiography confirm the results of the 64 SLICE CT concerning patients having significant stenosis, but the MDCT overestimate the degree of stenosis only in o patient.

Conclusion:

In a routine clinical practice, 64-slice CT detects with excellent accuracy a CAD in patients with complete LBBB., a normal MDCT in this clinical setting is a robust tool to act as a filter and avoid invasive diagnostic procedures.

Submission ID: 579

IMPACT OF PREHOSPITAL DELAY TIME ON MORTALITY IN WOMEN WITH ST-ELEVATION MYOCARDIAL INFARCTIONS

Ikram Chamtouri, Amdouni Nesrine, Wajih Abdallah, Faouzi Maatouk

Cardiology B Department – Fattouma Bourguiba University Hospital, Tunisia

Background:

Urgent reperfusion strategies in acute ST-elevation myocardial infarctions (STEMI) are crucial to reduce mortality. Several studies showed that female gender is one of the factors contributing to in hospital complications and mortality because of the long prehospital delay time. Hence, we assessed whether there are gender

differences in delay time before seeking care and its impact on in hospital mortality.

Methods:

The study was carried out on a retrospective registry enrolling 1609 patients presenting with STEMI in a Tunisian centre between January 1998 and January 2017. Risk factors, delay time to seek care and in-hospital prognosis were compared between men and women.

Results:

Out of the overall population, 352 (21.8%) were part of women. Compared to men, women were more likely to have arterial hypertension but less likely to be smokers and obese. Delay time >1 hour before seeking care was significantly less frequent in women (55.7% vs. 72.6% in men, $p<0.001$) Thrombolysis was significantly less utilized in women (27.3% vs. 35.4% in men, $p=0.004$), whereas the use of primary percutaneous coronary intervention was comparable between the two groups. The incidence of in-hospital complications was higher in women, and so was the in-hospital mortality rate (12.8% vs. 7.3%, $p=0.001$).

Conclusion:

Although the reduction of delay time to seek care among women, in hospital outcomes and mortality remains high.

Submission ID: 605

LOCALIZATION OF CORONARY ARTERY STENOSES IN PATIENTS WITH CORONARY ARTERY DISEASE: ROLE OF SPECKLE TRACKING IMAGING

Taamallah Karima, Guabsi Mayssam, Ataoui Sawsen, Chenik Sarra, Mahfoudhi Houaida, Chourabi Chadia, Fehri Wafa

Department of Cardiology; Military Hospital of Tunis, Tunisia

Background:

Two-dimensional (2D) speckle-tracking echocardiographic (STE) imaging is frequently performed in the assessment of cardiovascular diseases. We aimed to investigate the role of the global and territorial longitudinal strain (GLS and TLS) values assessed via 2D STE imaging to detect significant coronary artery disease (CAD) in patients without wall-motion abnormalities.

Methods:

This study enrolled 70 patients with the diagnosis of STEMI, NSTEMI, and stable angina pectoris and 50 healthy subjects. They underwent transthoracic echocardiography (TTE) to measure LV ejection fraction, 2-D-STE to measure GLS, and coronary angiography (CA). The subjects were divided into two groups: group 1 (70 patients) with significant (>70%) CAD, and group 2 (sex and age-matched 50 healthy patients). Images were obtained in the apical long-axis, four-chamber, and two-chamber views. The regional longitudinal systolic strain was measured in 17 myocardial segments and averaged to provide global longitudinal strain (LVGLS). Global and segmental longitudinal peak systolic strain were assessed and were correlated to the results of coronary angiography for each patient.

Results:

In the CAD group the mean age of patients was $60,89 \pm 10,4$, 61 patients were male (87%). GLS assessments demonstrated a statistically significant difference between CAD and control groups, with GLS values of $-16.39 \pm 2.46 \%$ and $-22.02 \pm 3.34 \%$ ($p < 0.001$). A negative correlation was found between the severity of CAD and GLS. There was an incremental significant decrease in GLS with an increasing number of coronary vessels involved. Multivariate analysis indicated that segmental longitudinal peak systolic strain (LPSS) also showed statistical significance for localization of the affected vessel for left anterior descending, left circumflex, and right coronary artery ($p=0.03$)

Conclusions:

Global longitudinal strain (GLS) assessed with 2D STE is a promising, easy to perform, and quick imaging method to predict CAD and to determine the localization of coronary artery stenoses.

Submission ID: 576

SUBCLINICAL DETECTION OF MYOCARDIAL IMPAIRMENT IN RHEUMATOID ARTHRITIS

Mahfoudhi Houaida

Cardiology department, Military Hospital of Tunis, Tunisia

Introduction:

Patients with rheumatoid arthritis (RA) have shorter life expectancy and their risk of cardiovascular death is more than 50 % higher than the rest of the population. Early myocardial dysfunction in RA patients may be detectable sooner using speckle-tracking echocardiography and would improve long term management.

The aim of this study was to detect subclinical pathologies in myocardial function in RA patients using standard and novel echocardiographic methods, and analyse their relationship to clinical characteristics of RA.

Methods:

We conducted a monocentric cross-sectional study on 36 rheumatoid arthritis patients without any history of cardiovascular disease and with non-altered left ventricular ejection fraction. After physical examination and blood testing, the rheumatoid arthritis group was matched with 36 healthy control subjects according to age, gender and body mass index.

Both groups underwent conventional echocardiography and speckle tracking echocardiography to measure global longitudinal strain.

Results:

No statistically significant difference was found between the two groups regarding conventional echocardiographic parameters. Myocardial deformation study revealed that rheumatoid arthritis patients had a significantly worse global longitudinal strain than healthy controls ($18.99 \pm 2.81\%$ vs $20.42 \pm 1.33\%$; $p=.015$). Moreover, a third of the rheumatoid arthritis patients (and no healthy controls) exhibited subclinical left ventricular systolic dysfunction ($GLS < 18\%$).

Our univariate analysis revealed that anaemia ($r=-0.368$, $p=.027$), age ($r=-0.365$, $p=.029$), diabetes mellitus ($r=-0.540$, $p=.001$) and E/A ($r=0.351$, $p=.036$) were significantly correlated with GLS while conventional indicators of disease severity like disease activity and disease duration had no significant association with GLS. Receiver operating characteristic curve analysis revealed haemoglobin as the best predictor for subclinical LVSD (AUC=0.752, 95% CI: 0.577-0.927, $p=.02$) when compared to Age and E/A. Multivariate logistic regression analysis showed that Anaemia was the only parameter that was independently associated with subclinical LVSD (OR: 11.39, 95% CI: 1.57-82.89, $p=.016$).

Conclusion:

Common RA comorbidities such as diabetes mellitus and anaemia appear to play a major role in the physiopathology of cardiac involvement and should be closely monitored

Submission ID: 602

ESTIMATION OF LEFT VENTRICULAR FILLING PRESSURE IN PATIENTS WITH ISCHEMIC CARDIOMYOPATHY: ROLE OF LEFT ATRIAL STRAIN

Taamallah Karima, Ataoui Sawsen, Guabsi Mayssam, Chourabi Chadia, Mahfoudhi Houaida, Chenik Sarra, Fehri Wafa

Department of Cardiology; Military Hospital of Tunis, Tunisia

Background:

Left ventricular filling pressure (LVFP) is raised by the compromised contraction and impaired ventricular compliance in ischemic cardiomyopathy with systolic dysfunction. Prompt diagnosis and staging of this condition are important for treatment strategy planning and making the prognosis. Two-dimensional speckle tracking echocardiography (2D-STE) has recently enabled the quantification of left atrial (LA) myocardial deformation.

The aim of this study was to determine the role of left atrial strain study to estimate LVFP.

Methods:

A total of 130 ischemic cardiomyopathy (ICM) patients were enrolled in this study. All patients underwent standard and Two-dimensional speckle tracking echocardiography (2D-STE). Global longitudinal LA strain during ventricular systole (GLAs-res) and strain during late diastole (GLAs-pump) were obtained. NT-pro-BNP levels were measured. The patients were assigned into two groups: normal LVFP (NLVFP group) and increased LVFP (LVFP group) according to E/A ratio, average E/e' ratio > 14, LA volume index > 34 ml/m², peak tricuspid regurgitation velocity > 2.8 m/s. Echocardiographic indicators of increased LVFP and NT-pro-BNP were compared with LA strain measured by 2D-STE.

Logistic regression analysis was used to determine independent predictors of increased LVFP.

Results:

In LVFP group: LAVi-max, and NT-pro-BNP were higher, whereas LA EF, LA emptying volume, GLAs-res, and GLAs-pump were lower.

A negative correlation was noted between GLAs-res and NT-pro-BNP, LAVi-max, and E/E' ratio. A negative correlation was also found between GLAs-pump and NT-pro-BNP, LAVi-min, and E/E' ratio. LAVi-max, LA activeEF, NT-pro-BNP, GLAs-res, and GLAs-pump were found to be independent predictors of increased LVFP.

Conclusion:

Our results suggest that LA function is impaired in patients with ICM. NT-pro-BNP levels associated with Left atrial reservoir and pump function parameters might be useful to estimate LVFP in these patients.

Submission ID: 604

IATROGENIC MYOCARDIAL PERFORATION

Houssef Thabet, Marwen Kacem, Aymen Hraiech, Ayoub Meddeb, Saeb Ben Saad, Rim Letaief, Abdelaziz Jaouadi, Nouha Mekki, Mehdi Slim, Imen Ben Ali, Sami Ouannes, Rim Gribaa, Elyes Neffati

Cardiology Department, CHU Sahloul, Sousse, Tunisia

Introduction:

The number of implantations of pacemakers and defibrillators is increasing, due to an expansion of indications and the aging of the general population. Handling the leads within the chambers of the heart may be at risk for myocardial perforation, arrhythmias or asystole. We have chosen to speak of cardiac perforation, the proper management of which is still poorly understood.

Method:

This was a descriptive, retrospective and single-center study, all patients diagnosed with cardiac perforation during the period between November 2018 and September 2020 were included. The clinical characteristics of patients having a cardiac perforation have been described, as well as the management.

Results:

256 intracardiac equipment implantations were carried out in the sahloul cardiology department during the study period distributed as follows: 43 single-chamber pacemakers, 150 double-chamber pacemakers, 43 triple-chamber pacemakers, 9 single-chamber defibrillators, 7 double-chamber defibrillators, 4 triple chamber defibrillators. Myocardial perforation occurred in 3 cases. The perforated heart chamber was the right ventricle in all cases. All of the probes used were stimulation probes and had active binding. The ventricular leads were all implanted at the apex. Two patients had post-implantation chest pain. A patient has a pacing defect in the unipolar configuration corrected by the change of the configuration to bipolar. At the TTE two patients had pericardial effusion. The diagnostic confirmation was made on the thoracic CT. The lead was removed by manual traction in all patients. New active fixation leads were inserted through the RV septum in two patients and at the apex in the third patient. The immediate course was favourable in all cases.

Conclusion:

Cardiac perforation is a serious but rare complication of implantation of pacemakers and implantable automatic defibrillators. All responsible probes had an active fixation mechanism and were implanted at the apex. In all patients, percutaneous extraction has been a safe and effective management approach.

Submission ID: 582

IMPACT OF DIABETES ON LONG TERM PROGNOSIS OF PATIENT WITH STEMI TREATED WITH PRIMARY PCI

Bouraoui H, Ghariani A, Sidiya KH, Frigui H, Saoudi W, Ben Abdesslam A, Bouhlel I, Mahdhaoui A, Ernez hajri S, Jeridi G
Farhat Hached Hospital Sousse, Tunisia

Objectives:

The main objective of our study was to evaluate the short and midterm prognosis of diabetic patients survived from STEMI treated by primary angioplasty.

Methods:

Consecutive patients with STEMI treated with primary PCI during 2016 to 2019 were evaluated and population was divided in two groups according to the diabetic status and followed for at least six months.

Results:

Among 225 patients (74% male) with mean age 60.9 years. 104 were type 2 diabetic patients on admission. intrahospital and 6 months mortality were significantly superior in the diabetic groups compared to non-diabetic groups respectively (2,2 vs 5,3 p=0.03) and (4 vs 9,3 p=0.003). Factors associated with poor prognosis in diabetic patients are diffuse coronary artery disease, high rate of procedural failure and poor ejection fraction.

Conclusion:

Despite modern Era of treatment of STEMI, diabetic patients still have a poor prognosis compared to non-diabetic patients. These results highlight the need for aggressive treatment of coronary risk factors among diabetic patients also particular attention should be given to diabetic patients who survived MI with left ventricular dysfunction to benefit from novel therapies.

Submission ID: 583

DELAY TO REPERFUSION IN STEMI: GAPS BETWEEN RECOMMENDATION AND REAL WORD

Bouraoui Hatem, Ghariani Anis, Sidiya Khalil, Ellini Hamza, Ben Abdesslam Aymen, Saoudi Wassim, Bouhlel Imen, Mahdhaoui a, Ernez Hajri Samia, Jeridi Gouider,

Farhat Hached Hospital Sousse Tunisia

Background:

The aim of our study was to evaluate factors associated with times to reperfusion in STEMI patients treated with PPCI and to compare them to standard of care.

Methods:

We assembled a cohort of 225 patients consecutively admitted to our cardiology department Farhat hached hospital sousse for PPCI between 2016 and 2019.

Results:

33 percent of patients received fibrinolysis than shifted to our hospital for rescue PCI all other patients received PPCI. 60 percent of them were transported to our department by ambulance from non-PCI centre in other regions.

The median delay was 13h for EMS transported patients from other regions and 4h for those self-transported to our hospital. Only 10 percent were reperfused less than 120 mn. Factors associated with long delay to reperfusion were source of referral and diabetic patients.

Conclusion:

Our results showed tremendous gaps between recommendations and real life for delay of reperfusion in patient suffering from STEMI, despite increasing number of PCI centres in our country, STEMI network system still needs more organisation to minimize delay, thereby improving clinical outcomes stemi.

Submission ID: 584

FEMOROPOPLITEAL ANGIOPLASTY: SHORT AND MID-TERM RESULTS: RESULTS OF A COHORT OF 289 CASES

Malek Ben Mrad, Derbel Bilel, Ben Hammia Mohamed, Miri Rim, Denguir Raouef

Cardiovascular Surgery Department, Rabta hospital; Tunis

Percutaneous endovascular therapy is becoming a primary option for managing femoropopliteal occlusive disease. The purpose of this study was to evaluate the mid-term results of endovascular treatment of femoropopliteal arterial disease in a contemporary series of patients with chronic lower extremity ischemia.

Methods:

Femoropopliteal percutaneous transluminal angioplasty was performed on 291 consecutive limbs (289 patients) from January 2012 to January 2018.

Study endpoints, including primary patency, and limb salvage, were assessed by Kaplan-Meier life-table analysis, and factors predictive of hemodynamic or clinical failure, or both, were evaluated by univariate and multivariate methods.

Results:

In our study, 87.6% of patients had critical limb ischemia. Lesions were classified as Trans-Atlantic Inter-Society Consensus (TASC) A (43%), B (43%), C (7%), and D (7%). PTA was confined to the superficial femoral segment in 202 procedures (70%), to the popliteal artery in 32 operations (11%) and in 55 interventions (19%) patients underwent both femoral and popliteal angioplasty.

Femoropopliteal interventions included angioplasty only in 125 cases (43.2%), and the remaining (56.8%) received at least one stent. Technical success was achieved in 98.7% of patients, with three deaths and a major morbidity rate of 15, 43%. The actuarial primary patency at 12 and 36 month was 65.4% and 40.2%, respectively, 55 peripheral reinterventions were performed after femoropopliteal axis occlusion, resulting in an actuarial primary limb preservation rate of 94.4 at 12 months. Comparison between angioplasty only and the use of stent show no difference in primary patency ($p=0.832$) and limb salvage ($p=0.67$). Negative predictors of primary patency determined by univariate analysis included popliteal location ($p<0.001$) and TASC D ($p<0.001$). However, diabetes mellitus ($p=0.001$) and poor run off ($p<0.001$) were the principal predictive factors of limb loss.

Conclusion:

Femoropopliteal angioplasty can be performed with a low perioperative morbidity and mortality. Intermediate primary patency is directly related to TASC classification and popliteal localization. These data suggest that it would be appropriate to use percutaneous transluminal angioplasty as initial therapy for chronic femoropopliteal occlusive disease especially in patients with heavily morbidities.

Submission ID: 585

MECHANICAL THROMBECTOMY IN ACUTE THROMBOSIS OF DIALYSIS ARTERIOVENOUS FISTULAE: REPORT ON THE EXPERIENCE OF A TUNISIAN CENTRE

Ben Mrad Melek, Ben Hammia Mohammed, Ben Salem Malek, Miri Rim, Ben Fatma Lila, Denguir Raouf

Cardiovascular Surgery department, Rabta Hospital, Tunisia / The nephrology department, Rabta Hospital, Tunisia

Background:

Chronic end-stage renal disease is a major public health problem, the number of patients treated by haemodialysis and therefore requiring a vascular access has shown an exponential rise. Thrombosis other this latter is a severe complication causing the failure of the vascular access, percutaneous mechanical thrombectomy has become widespread in the management of this disease and has good immediate result. Our review analyse outcome of mechanical thrombectomy by Manual Catheter-Directed Aspiration in acute thrombosis of vascular access for haemodialysis.

Methods:

From June 2016 to September 2019, 8 percutaneous procedures were performed in 7 patients presenting with acute thrombosis of AVF and/or AVG for dialysis. The procedures were performed between 24h hours and 11 days after the occurrence of thrombosis. The type of access was upper-arm fistula for all the patients. All the procedures involve two stages: removal of the clots and treatment of the cause of thrombosis commonly a stenosis. Our mechanical thrombectomy used two categories of devices: direct contact devices like Fogarty catheter and compliant balloon; angiographic catheter removing the thrombus by thrombo-aspiration. This technique is safe and has immediate technical success. The second part of the procedure consisted in managing systematically stenoses unmasked at de-clotting with conventional or high-pressure balloon angioplasty. Treatment outcomes were evaluated on the basis of technical procedural success and patency after correction of the clotted fistula.

Results:

Technical success with restauration of flow was established for 100% of patients which is similar to other studies in the literature 76%-100%. Only one case of early reclusion was seen requiring confection of another AVF. No technical or clinical complications were reported. The duration of the procedure ranged from 58 min to 245 min. The primary patency rate at 12 months was 54%, the secondary primary rate was 72%. This review is limited by the small number of patient and the lack of long-term follow-up.

Conclusion:

In conclusion acute thrombotic occlusion of AVF and/or AVG is a serious complication which can be easily treated by a safe and effective percutaneous method.

However, our review shows the efficacy of mechanic thromboaspiration in vascular access thrombosis.

Submission ID: 614

WE DID EVERYTHING, BUT....

Houssef Thabet, Mehdi Slim, Marwen Kacem, Ayoub Meddeb, Houada Ghardallou, Ahmed Sghaier, Nabil Ajmi, Saeb Ben Saad, Rim Letaief, Marwa Abdallah, Rim Gribaa, Imen Ben Ali, Sami Ouannes, Afef Lagren, Elyes Neffati

Service de cardiologie, CHU Sahloul Sousse, Tunisia

Introduction:

It is certain that myocardial infarction in children is rare, but it should be evoked as a principle. An ECG should be done in any child who consults for chest pain that is isolated or associated with other symptoms.

Clinical presentation:

We report the case of a 12-year-old boy who had no significant personal history and whose family history had familial hypercholesterolemia type II and sudden death in family. The boy was brought to the emergency room by his mother with constricting chest pain that occurred while at rest. The physical examination revealed a tendon xanthoma of the elbows and knees, a bilateral genotoxin. Biological assessment showed: US Troponins = 2500ng/ml. Total cholesterol = 20mmol/l, LDLc = 17mmol/l, triglycerides = 3.3mmol/l. The ECG showed an ST segment elevation of 2 mm in AVR, and a diffuse horizontal ST depression in the other leads. The diagnosis was a high-risk NSTEMI. The patient received 300 mg of clopidogrel, 250 mg of aspirin orally and 60 IU/kg of heparin. TTE found good LV systolic function, segmental kinetics were corrected. Coronary angiography was performed with difficult selective catheterization of the left common trunk. The patient had a tight ostial stenosis of the LCA. The intubation of the right coronary artery was difficult, so a coronary CT scan was completed which revealed severe stenosis of the RCA ostium. We decided to do an angioplasty of the left common trunk, the procedure took place without incident (active stent 2.75x24mm). The atherosclerosis assessment, in particular of the supraoptic trunks and the lower limbs, was normal. A year later, the child comes back for a recurrence of angina at rest. Control coronarography found interstent restenosis of the LCA. The decision was a double coronary artery bypass graft. Day 1 post CABG, the child was extubated. 4 hours after orotracheal extubation, arterial hypotension onset associated with vomiting and epigastralgia. An ECG was taken showing a STEMI which warranted urgent reintubation, conditioning and coronary angiography. Angiographic control showed that the CD-AMID bridge was occluded. The course was marked by cardiopulmonary arrest in the KT room.

Conclusion:

Acute coronary syndromes are rare in children, familial percholesterolemia is one of the aetiologies. The management is similar to that of adults and is based on the revascularization of the coronary arteries.

Submission ID: 566

NEW-ONSET ATRIAL FIBRILLATION AFTER ACUTE CORONARY SYNDROME: PREVALENCE, PREDICTIVE FACTORS AND PROGNOSIS

Ben Hlima Manel, Yaakoubi Wael, Boudiche Selim, Rekik Bassem, Mghaith Fathia, Larbi Nourddine, Abdejill Farhati, Mourali Med Sami

RABTA Hospital, Tunisia

Introduction:

New-onset AF atrial fibrillation (NOAF) frequently complicates acute coronary syndromes (ACS) leading to adverse outcomes

in the short and long term. The reported incidence ranges from 2 to 37% according to recent studies and a number of factors have consistently been shown to be associated with this arrhythmia.

The aim of the study: was to determine the prevalence of NOAF in a population of patients admitted for ACS and to identify its predictive factors and study their prognosis.

Methods:

We carried out a prospective, descriptive and comparative observational study during a period of 10 months from January 2019 to November 2019 in the Cardiology department of the Rabta hospital. We included in our study consecutively hospitalized patients with acute coronary syndrome (ACS) who did not have a previous diagnosis of AF.

Results:

In our study, we included 404 patients hospitalized for ACS. The prevalence of NOAF was 10%. In the multivariate analytical study, we retained as independent predictors of NOAF: age greater than 62 years ($p = 0.04$; adjusted OR = 4.83; CI95%: 1.07-21.77), chronic renal failure ($p = 0.043$; adjusted OR = 6.61; CI95%: 1.06-35.80), history of stroke ($p = 0.002$; adjusted OR = 44.51; CI95%: 3.97-498.10) and finally uricemia ≥ 62 mg / l ($p = 0.04$; adjusted OR = 4.4; CI95%: 1.06-18.15). NOAF was associated with a higher in-hospital mortality (5% vs. 0.5% in the group without AF; $p = 0.04$) as well as a higher incidence of in-hospital major cardiovascular events (69 % versus 24%; $p = 0.009$). For the 183 patients followed over a mean period of 12 months, the NOAF was associated with a higher extra-hospital mortality (13% vs 6% in the group without AF; $p = 0.03$) but there was not significant difference between patients with and without AF for major cardiovascular events.

Conclusion:

The prevalence of NOAF in patients with ACS was 10%. Its systematic screening in these patients appears to be a relevant approach because of the strong association between the two pathologies in this population, and the pejorative impact on the prognosis of this arrhythmia.

Submission ID: 755

REAL TIME-2D AND 3D TRANSESOPHAGEAL ECHOCARDIOGRAPHY ASSESSMENT OF ATRIAL SEPTAL DEFECTS

Mahfoudhi Houaida, Taamallah Karima, Chenik Sarra, Chenik Sarra, Chourabi Chadia, Haggui Abdeddayem, Hajlaoui Nadhem, Lahidheb Dhaker, FEHRI Wafa

Cardiology Departement, Military Hospital of Tunis, Tunisia

Introduction:

Real-time three-dimensional transesophageal echocardiography (RT3D-TEE) has emerged as a revolutionary innovation in cardiovascular imaging that provides dramatically improved anatomic assessment of cardiac structures, such as atrial septal defects (ASDs). The aim of this study was to evaluate the contribution of RT3D- TEE in the morphological and anatomical study of ASD compared to 2D multiplanar TEE.

Methods:

Ten patients with ASDs were imaged using 2D and RT 3D TEE. ASD shape and size were assessed using both methods. Maximal ASD dimensions obtained by 3D and 2D TEE were compared.

Results:

Of the 10 ASDs, 3 were circular, 6 were oval, and 1 was complex in shape. The mean maximal dimension was larger by 3D TEE

compared with 2D TEE. There was no difference in the study of the rim size by either modality, but for complex-shaped defects, the study by 3D TEE was more performed than that by 2D TEE. 8 of the 10 patients underwent transcatheter ASD closure. Closure device size was based on findings on 3D TEE.

Conclusions:

RT3D-TEE is becoming a more routinely established imaging technique for structural heart disease and offers a more comprehensive understanding of secundum type ASDs compared to 2D TTE. It significantly expands the diagnostic capabilities of cardiac ultrasound, allowing the visualization of cardiac anatomy, pathology, and devices in a 3D format easily appreciated by operators. RT3D-TEE should be an essential imaging tool for guiding and assessing ASD device closure.

Submission ID: 574

BENEFITS OF MEASURING MAXIMUM MYOCARDIAL OXYGEN CONSUMPTION IN CHILDREN WITH CONGENITAL HEART DISEASE

Mahfoudhi Houaida

Cardiologie Département of Military Hôpital, Tunisia

Introduction:

The cardiopulmonary exercise test (CPET) in paediatric cardiology differs from that performed in adult cardiology. These children exhibit variable cardiovascular responses during exercise testing including myocardial oxygen uptake. We sought to compare the cardiopulmonary condition of children with congenital heart disease to that of controls adjusted for age and sex. We will also identify the clinical features associated with maximal myocardial oxygen consumption (VO₂ max) in this population.

Methods and Results:

This is a prospective cross-sectional study, including a total of 54 children (27 operated on for congenital heart disease and 27 controls) who underwent a CPET full cardiopulmonary stress test. We studied the clinical characteristics of each group. Congenital heart disease has been classified according to the Bethesda classification based on its complexity. The mean age of our patients was 13.96 years ± 4 years Vs 11.32 ± 3.72 years in the control group (p = 0.07).

Group of operated on congenital heart disease Control group P
Sex - Male: 15 (55.6%) - Male: 11 (40.7%) = 0.27

Weight in Kg - Female: 12 (44.4%) - Female: 16 (59.3%) = 0.18

Body mass index in kg / m² - 46.48 ± 15.71 - 40.80 ± 14.69 = 0.03

Types of Congenital Heart Disease According to the Bethesda Classification - Medium complexity (28.6%)

- Not complex (42.9%)

Indication of cardiorespiratory test in the control group - Chest pain (22.2%)

MVO₂max in ml / Kg / min - 20.08 ± 4.09 - 17.77 ± 3.92 <0.01

In our work, the magnitude of the difference in VO₂ max in children with congenital heart disease was significantly less than in normal children. This is probably due to the cardio thoracic surgery and the evolution of the operated on congenital heart disease.

Conclusion:

Physical deconditioning affects three times more children with operated on congenital heart disease than controls. We suggest doing CPET in the routine follow-up of these children. This will remain an important parameter in deciding the aptitude of these children for sport.

Submission ID: 612

LEFT VENTRICULAR RAPID PACING IN TAVI

Hajlaoui Nadhem, Anouar Yassine

Military Hospital of Tunis, Tunisia

Introduction:

Rapid pacing is necessary during balloon-expandable TAVI in order to produce cardiac standstill and stable device positioning.

Classic temporary pacing requires a central venous vascular access for placing the pacing catheter in the right ventricle (RV) which is likely to generate complications.

However, effective cardiac pacing can also be achieved using a unipolar electrode in the left ventricle (LV).

We will describe the technique of left ventricular rapid pacing via the 0.035" valve delivery guidewire using two alligator clamps.

Clinical Case:

Our patient is an 87 years old female admitted with complaints of progressive dyspnoea.

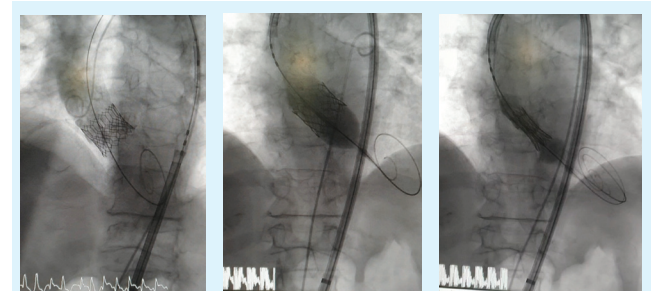
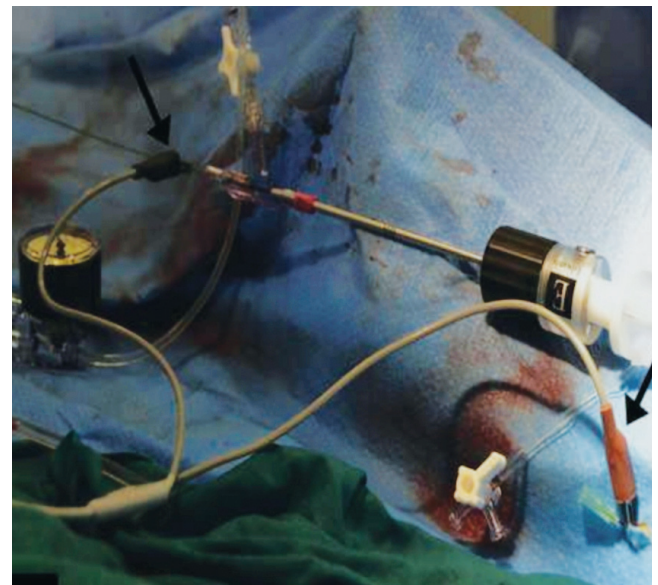
Her past medical history included COPD, HTN, CAD treated with PCI 3 months prior to the admission, and severe calcific aortic stenosis (AVA = 0.7 cm²).

The case was discussed in a multidisciplinary team meeting, in which we decided to perform a TAVI using transcatheter Edwards SAPIEN 3 valve (26 mm).

After the patient and her family consented, the procedure was carried out.

Conclusion:

Rapid LV pacing during balloon expandable TAVI procedure is as safe and efficient as the classic RV pacing, it is a simple and reproducible technique that prevents the complications related to RV temporary pacing.



Submission ID: 609

ANALYSIS OF THE PERFORMANCE OF THE EUROSCORE II ACCORDING TO THE CALIBRATION APPROACH IN A TUNISIAN POPULATION

Amani Maatouk, Mohamed Mahjoub, Imene Mgarrech, Maatouk Iyed, Taieb Cherif, Chokri Kortas, Sofiane Jerbi, Mansour Njah

Department of Cardiovascular and Thoracic Surgery, Sahloul University Hospital, Sousse, Tunisia; Hospital Hygiene Service, University Hospital Centre Farhat Hached, Sousse, Tunisia; Department of Medical Intensive Care, University Hospital Taher Sfar, Mahdia, Tunisia

Background:

Cardiac surgery risk scores are used to estimate surgical mortality based on patient characteristics and surgical modalities. One of the most widely used scores is the EuroSCORE II which needs to be validated in developing countries such as Tunisia. We aimed to evaluate the performance of the EuroSCORE II according to the calibration approach in a Tunisian population.

Methods:

This is a retrospective cross-sectional study conducted at the Cardiovascular and Thoracic Surgery Department of the University Hospital Sahloul of Sousse (Tunisia) from January 2015 to December 2016. It included 418 adults undergoing cardiac surgery under extracorporeal circulation. Data were collected from

the archived patient records. The EuroSCORE II was calculated for each patient using the validated application on the www.euroscore.org website. Data analysis was performed using the Statistical Package for Social Sciences (SPSS) version 20.0. The EuroSCORE II performance was assessed by the calibration analysis using the Hosmer-Lemeshow statistics.

Results:

In total, 418 patients participated in the study. The majority of respondents were male (58.6%). The mean age was 55.84 ± 13.84 years. Patients underwent different types of cardiac surgery mainly represented by valve surgery (48.8%). The global mortality rate was 9.3%. The observed mortality was 6.8%, 8.3% and 23.3% respectively for the coronary subgroup, the valvular subgroup and the urgency subgroup. According to the calibration analysis, Hosmer-Lemeshow test for all groups showed a p value ≥ 0.05 (0.638 for the total population, 0.543 for the coronary subgroup, 0.179 for the valvular subgroup, 0.082 for the urgency subgroup). No statistically significant difference was found between expected and observed mortality.

Conclusion:

Our study showed a good calibration of The EuroSCORE II in favour of its acceptable performance in our population under reserve of the small sample size. Therefore, prospective multicenter studies on the performance of this model in Tunisia should be conducted on larger samples in order to develop an adapted version.

Submission ID: 629

PROGNOSTIC VALUE OF PREOPERATIVE HIGHLY-SENSITIVE TROPONIN IN PREECLAMPSIA

Bassem Rekik, Abderrahmen Ben Gharbia, Syrine Chaouch, Selim Boudiche, Manel Ben Halima, Fourat Zouari, Sana Ouali, Fathia Mgaïeth, Mohamed Sami Mourali

La Rabta Hospital Tunis, Tunisia

Pre-eclampsia is a multisystem disorder that involves vascular endothelial dysfunction and diffuse inflammatory response. High-sensitivity troponin (hs-cTn-I) levels in pre-eclampsia are controversial. The objective of this study was to assess the prognostic value of preoperative hyper-sensitive troponin in preeclampsia.

Methods:

It was a prospective study over a period of 4 months. We included patients whose pregnancies were complicated by preeclampsia. The exclusion criteria were conditions that may cause an elevation of hs-cTnI. The hs-cTn-I levels of all patients were measured preoperatively. The discriminative value of the preoperative hs-cTnI allowing to predict the onset of complications was evaluated by the ROC curve.

Results:

A total of seventy-seven patients were included, 66% of whom presented with a severe form of preeclampsia. The average term was 34 weeks' gestation. Complications occurred in 22% of cases. The area under the ROC curve predicting the onset of complications for hs-cTnI measured 0.817 (95% CI: (0.685-0.948)). For a Youden index of 0.573, the preoperative hs-cTnI cutoff was 6.3 ng / l (sensitivity 70.6% / specificity 86.6% / $p < 0.0001$). According to this cut-off value, the patients were assigned into two groups as the pre-eclamptic pregnant group whose hs-cTn-I levels was above the calculated cut-off (Group A n = 20), and those whose hs-cTn-I levels was below the cut-off (group B n=57). There was a higher rate of severe pre-eclampsia, higher systolic and mean arterial pressure values, higher serum creatinine levels as well as a higher rate of complications in

group A with a statistically significant difference. Both groups were comparable demographically, obstetrically, clinically and biologically. Systolic, diastolic, and mean blood pressure values were not correlated with the occurrence of complications.

Conclusion:

According to the results of our study, increased values of preoperative hs-cTnI may predict the onset of complications in the pre-eclamptic pregnant.

Submission ID: 627

SIX-YEAR FOLLOW UP OF LEFT ATRIAL APPENDAGE CLOSURE WITH WATCHMAN DEVICE

Ikram CHAMTOURI, wajih Abdallah, walid Jomaa, Khaldoun Ben Hamda, Faouzi Maatouk

Cardiology B department, Tunisia

Background:

Stroke is a major complication of non-valvular atrial fibrillation (AF). Despite its proven efficacy in stroke prevention, oral anticoagulation (OAC) is associated with significant increase in bleeding complications. New techniques such as percutaneous left atrial appendage (LAA) closure were developed.

Aim:

This study aimed to evaluate outcomes at six years after percutaneous LAA closure in Tunisian patients presenting with non-valvular AF.

Methods:

Nineteen patients with non-valvular AF were prospectively enrolled for percutaneous LAA closure between February 2013 and June 2014. The Watchman device was used in all LAA closure procedures. Clinical and echocardiographic follow-up were carried-out at 1, 6, 12 months and yearly in all patients. Long term outcomes at six-year follow up were evaluated.

Results:

Mean age was 68.4 ± 7.5 years. Thirteen patients were female, 16 patients had hypertension, 12 patients had diabetes mellitus and 7 patients had a history of stroke or transient ischemic attack (TIA). Average CHA₂DS₂VASc (Congestive Heart Failure/ Left Ventricular Dysfunction, Hypertension, Age \geq 75, Diabetes mellitus, Stroke/Transient Ischemic Attack/Thromboembolic event, Vascular disease, Age \geq 65, Sex category) score was 4.2 ± 1.5 and HASBLED (Hypertension, Abnormal renal/liver function, Stroke, Bleeding tendency, Labile INR, Age \geq 65, Drugs) score was 3.5 ± 1 . Ten patients had a history of severe bleeding. Procedural success was achieved in all patients. Pericardial effusion with tamponade was reported in one case. No post-procedural death was reported. Follow-up at six years did not show neither stroke or thromboembolic event or Watchman device thrombosis. One case of mortality was caused by an extra cardiovascular problem at four years after LAA closure.

Conclusion:

According to this study, LAA closure with Watchman device is safe and effective in reducing stroke in patients with non valvular AF and contra indication to OAC.

Submission ID: 730

CORRELATION BETWEEN THE SEVERITY OF CIRRHOSIS AND ELECTRO-ECHOCARDIOGRAPHIC PARAMETERS

Housseem Thabet, Marwen Kacem, Ayoub Meddeb, Saeb Ben Saad, Rim Letaief, Rim Gribaa, Mehdi Slim, Imen Ben Ali, Elyes Neffati, Wafa Dahmani, Aida Slama, Ahmed Sghaier

Service de gastrologie, Hôpital universitaire Sahloul, Sousse, Tunisia

Introduction:

Cirrhotic cardiomyopathy (CCM) is currently emerging as a unique clinical entity occurring in cirrhosis, which is characterized by a constellation of structural, functional, and electrophysiological cardiac abnormalities. Its diagnosis is mainly based on echocardiography.

Patients and methods:

This is a cross-sectional study of patients followed for cirrhosis during the period from 2016 to 2017. Each patient underwent a clinical examination, an ECG and a cardiac ultrasound. The diagnosis of CCM was retained on the presence of systolic and / or diastolic dysfunction.

Results:

During the study period, 76 cirrhotic were collected. The mean age of the patients was 54 ± 11.8 years with ranges ranging from 18 to 79 years. The study population consisted of 45 men (59% of patients) and 31 women (41%). The sex ratio (Male / Female) of 1.4. Twenty-two patients (29%) presented with one or more co-morbidity(s) associated with cirrhosis. It was mainly type 2 diabetes, found in 7 patients (9.2%). 11 patients were smokers. Occasional alcohol consumption was found in 6 patients. Cirrhosis was of viral origin in 35 cases (46%). Elsewhere, it was alcoholic cirrhosis, dysimmune cirrhosis, non-alcoholic steatohepatitis, and cryptogenic cirrhosis. Cirrhosis was classified as CHILD PUGH B in the majority of cases (44.7%). 9 patients (11.8%) had cirrhosis CHILD PUGH CA on ECG: the corrected QT was prolonged in 33 patients (43.5%). Based on the consensus diagnostic criteria of 2005, systolic dysfunction and diastolic dysfunction were present in 5.3% (n = 4) and 51.3% (n = 39), respectively. The prevalence of CCM was 53.9% (n = 41). Of all the echocardiographic parameters studied, only the volume of the left atrium was positively correlated

with both CHILD PUGH score (p = 0.002) and MELD score (p = 0.004). There was also a positive correlation, statistically significant, between the QT interval and the two cirrhosis severity scores: MELD and CHILD PUGH.

Conclusion:

Our study showed that CCM is a common condition affecting older, female patients with advanced hepatopathy. QT interval and LA volume were correlated with the severity of cirrhosis.

Submission ID: 625

CHARACTERISTICS OF ACUTE CORONARY SYNDROME WITHOUT ST SEGMENT ELEVATION IN ELDERLY

Amani Farah, Amin Boussetta, Marwa Chebbi, Mohamed Amine Soula, Marouen Sta, Sabrina Soudani, Habiba Drissa

Introduction:

Since coronary heart disease is the leading cause of death in the world, its clinical presentation is all the less typical and its prognosis darker as it occurs in elderly and fragile patients. The purpose of our study was to determine whether in the acute coronary syndrome (ACS) without ST segment elevation is there a difference between young and elderly patients in terms of epidemiological, clinical, angiographic, therapeutic and prognostic data.

Method:

Our study was retrospective, observational and single-center involving 170 patients (95 young patients and 75 elderly patients) admitted for ACS without ST segment elevation to the "Adults" cardiology department at the CHU la Rabta between July 2010 and July 2017. Our patients were divided into 2 groups: a group of patients aged 65 years or over (group A) and a second group aged less than 65 years (group B).

Results:

Elderly patients accumulated more risk factors than younger subjects. They were more often hypertensive and dyslipidemic and less smoking than the younger ones. chest pain was more frequently atypical in group A, leading them to consult later. Despite their higher ischemic risk, (high Grace Score: 77.3% versus 63.2% in young patients (p = 0.04)) elderly patients had less often benefited from an invasive strategy.

On coronary angiography, subjects over 65 years of age had tritronascular lesions and chronic occlusions more frequently than younger subjects with respectively (33.8% and 14.1% versus 17.2% and 2.1%). Myocardial revascularization was offered less frequently in elderly patients than in younger subjects (49% versus 78%) (p = 0.004) and in particular they benefited less from angioplasty (7% versus 10.6% in the youngest).

Elderly patients were generally more at risk of events at one year than younger ones. They had presented more MACE (death / angina recurrence / revascularization) during the course with a significant difference and a higher mortality at 1 year.

At the end of our multivariate analysis, age emerged as an independent predictor of 1-year mortality.

Conclusion:

ACS without ST elevation elevation in the elderly, a serious pathology often underdiagnosed, is associated with a higher ischemic risk than in young subjects. Paradoxically, he benefited from less aggressive treatment and less adequate management responsible for a worse long-term prognosis and a higher mortality rate.

Submission ID: 623

VENTRICULAR DIASTOLIC DYSFUNCTION IN SICKLE CELL ANEMIA

Chenik Sarra, Bouslimi Abyr, Ataoui Sawsen, Mahfoudhi Houaida, Chourabi Chedia, Taamallah Karima, Sadok Hannachi, Barakizou Hager, Wafa Fehri

Cardiology Department / Paediatric department, Military Hospital of Tunis, Tunisia

Background:

Cardiac failure from myocardial iron deposition is a severe complication in patients with transfusion-related iron overload. Progressive heart damage from iron overload can cause left ventricular systolic and diastolic dysfunction in patients with hematologic disorders. Since non-transfused patients with sickle cell anaemia (SCA) have a high incidence of diastolic dysfunction, we investigated the diastolic left ventricular function of children with SCA.

Methods:

Thirty Children (≤ 18 years) with SCA were eligible and age and sex matched with a control group. Echocardiographic data were used for comparison.

Results:

Among 30 children with SCA (median age, 11,8 years). Echocardiography showed a high prevalence of diastolic dysfunction. The study of diastolic function showed an abnormality of relaxation in 16,7% of patients with ($E / A < 1$), an abnormality of compliance in 46,7% of patients and the rest had a normal E / A ratio. The area and the volume of the left atrium was significantly larger in SCA group ($15,2 \text{ cm}^2$ vs $11,03 \text{ cm}^2$, $p < 0,001$) and ($34,9 \text{ ml/m}^2$ vs $16,33 \text{ ml/m}^2$, $p < 0,001$). There was significant difference between the two groups concerning TDE (deceleration time) and the E/A ratio were significantly higher in SCA group (172 ms vs 127 ms , $p = 0,002$) and ($2,11 \pm 0,98$ vs $1,59 \pm 0,29$, $p < 0,009$) respectively.

Conclusions:

SCA is known to impact the left ventricle, similar to other chronic anaemic states. routine echocardiographic studies should be performed as a part of continuous medical care to identify high-risk patients who may benefit from additional investigation and therapy.

Submission ID: 624

PERCUTANEOUS TRANSLUMINAL STENTING OF THE COMMON CAROTID ARTERY IN NONSPECIFIC AORTOARTERITIS: A CASE REPORT

Ben Mrad Melek, Lagha Amal, Hammamia Nadia, Souid Asma, Ben Hmida Yasmine, Ben sAlem Malek, Derbel Bilel, Denguir Raouf

Cardiovascular Surgery Departement, Rabta Hospital, Tunis, Tunisia

Introduction:

Takayasu arteritis is a challenging autoimmune disease that characteristically affects the aorta and its primary branches especially in young women. It is primarily treated by pharmacologic therapy, but surgical or endovascular treatment may be required when there are cerebral manifestations, to prevent a catastrophic outcome.

We report an original case of an endovascular management using a drug eluting stent of a supra-aortic arterial occlusive disease due to Takayasu arteritis, in a young Tunisian patient.

Case Report:

In our report, we describe the case of a 27-year-old Tunisian female with Takayasu disease who underwent endovascular revascularization due to cerebrovascular symptoms refractory to medical therapy. She developed episodes of syncope and general weakness for four months. Angioscan showed occlusion of the left subclavian artery, stenosis of the left common carotid artery, occlusion of the right common carotid artery and the right subclavian artery. First, the patient had an angioplasty with 5 mm normal balloon, with immediate recoil, and then she had a stenting of the left common carotid artery using a coronary eluting stent 4, 5*34mm, followed by a complementary intra-stent inflation of a 5*20mm balloon.

The procedure and post-operative recovery were successful. The 3-month check-up reveals the resolution of all symptoms.

Conclusion

Certainly surgical revascularization of supraoptic trunks lesions associated with Takayasu remains the gold standard treatment, but endovascular treatment, especially carotid stenting, may represent a feasible and less invasive alternative.

Submission ID: 630

SUBINTIMAL RECANALIZATION OF AN OCCLUDED COMMON ILIAC STENT: A CASE REPORT

Ben Mrad Melek, Mlayhi Sobhi, Jenni Haifa, Ben Abdellatif Bouhaina, Ben Hammamia Mohamed, Denguir Raouf

Cardiovascular Surgery Department, Rabta Hospital, Tunis, Tunisia

Introduction:

Iliac stent thrombosis is problematic. When intraluminal stent recanalization is not possible, surgery is often indicated. Subintimal recanalisation with crushing of the old stent is known for coronary stent but not for peripheral artery stent.

We report in this case, a new endovascular approach to manage thrombosed iliac stent when endoluminal catheterism is not possible.

Case Report:

A 55 years old woman was admitted in our department for a critical lower limb ischemia due to thrombosis of left common iliac stent implanted 2 years earlier for claudication. The ankle-brachial index was 0.5.

Our initial strategy was to cross intraluminally the occlusion and to use a drug-eluting balloon.

However, we failed to achieve an intraluminally stent recanalization, so we performed a subintimal recanalization of the occluded stent. The wire crossed the occlusion completely outside stent through the subintimal space. Firstly, we performed a balloon angioplasty, a 7mm balloon was inflated at eight ATM pressure and contributed in crushing of the thrombosed stent.

Therefore, we deployed an 8 x 112 mm Wall-Stent (Boston Scientific), covering all the common and external iliac artery.

The final angiogram showed a patent iliac conduit with a total flattening of the old stent.

Post-operative course was favourable with symptomatic relief. The ankle-brachial index was improved to 0.85, and duplex ultrasound showed patency of the iliac artery at 1 and 6 months.

Conclusion:

Subintimal recanalisation of an occluded stent is not only feasible for coronary stent thrombosis but can also be performed for peripheral arterial stent thrombosis especially when intraluminally stent recanalization cannot be achieved.

Submission ID: 654

ARTERIAL THROMBOSIS IN A PATIENT WITH CORONAVIRUS DISEASE

Zeineb Oumaya, Khadija Mzoughi, Bouthaina Besbes, Imtine Ben Mrad, Sofien Kamoun, Malek Marouani, Fethia Ben Moussa, Sana Fennira, Ihsen Zairi, Sondos Kraiem

Service de Cardiologie Hôpital Habib Thameur, Tunisia

Background:

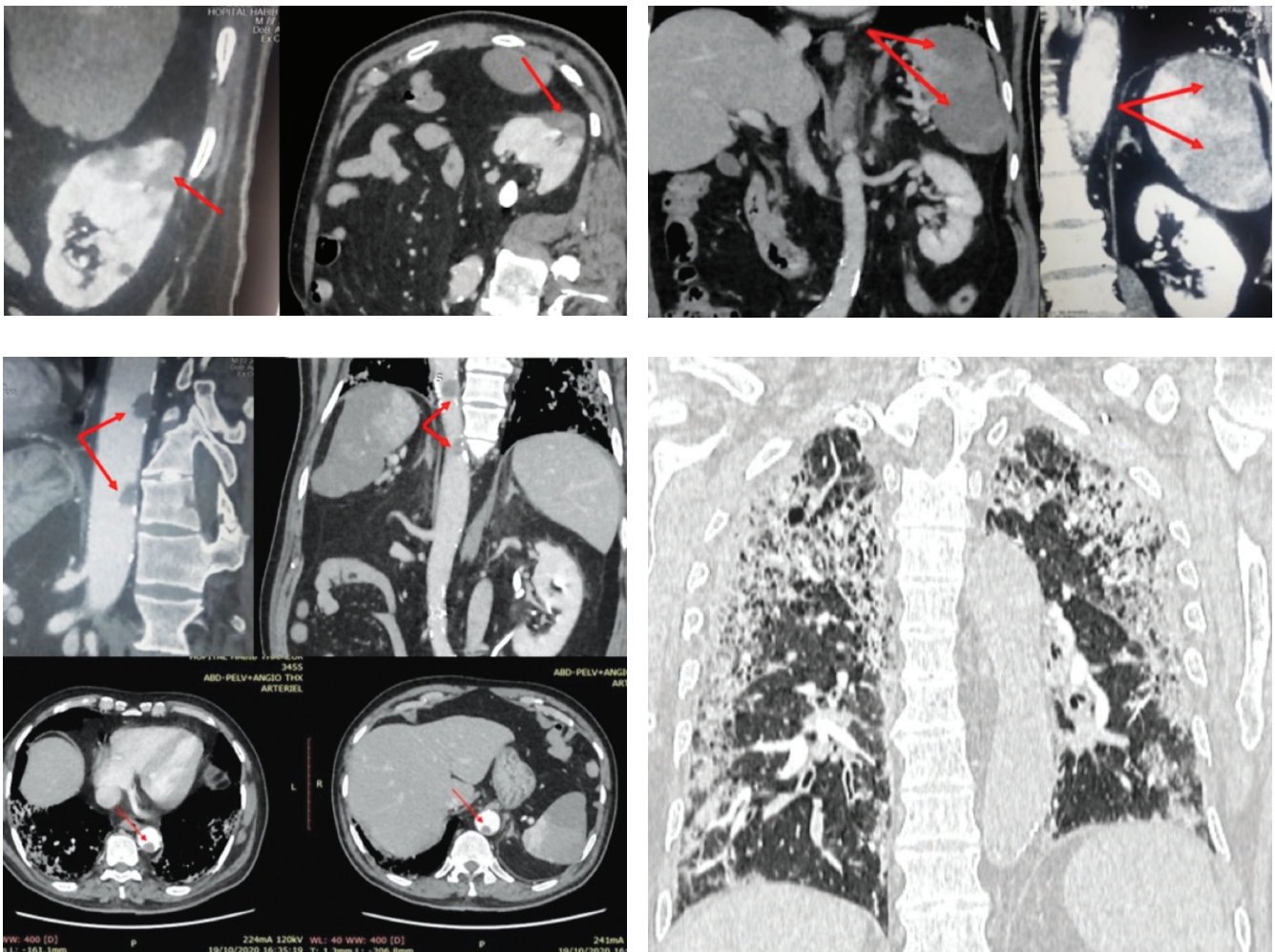
Since the emergence of the COVID-19 pandemic, there is an increasing evidence that affected patients have a higher incidence of thrombotic complications than the general population. This coagulopathy appears to be responsible for venous and less commonly arterial thromboembolic complications, in up to 50% of COVID-19 patients with severe manifestations. Abnormal coagulation parameters are considered a warning sign of such complications. The COVID-19 patients' laboratory findings include thrombocytopenia, elevated D-dimer levels, prolonged prothrombin time and disseminated intravascular coagulation. However, the exact underlying mechanism is not yet well understood. The evolution is rarely favorable on anticoagulant and anti-aggregating therapy, as in the case reported below.

Case report:

We report herein a case of aortic thrombosis in a 77-year-old patient with a history of hypertension and atrial fibrillation on Vitamin K antagonist (VKA), who presented to the emergency department with dyspnoea and abdominal pain. On examination, he was hemodynamically stable, but polypneic and hypoxic with 76% SpO2 in ambient air, his abdomen was painful on palpation. The ECG showed atrial fibrillation at 100 bpm without any repolarization disorder. He had lymphopenia, a prominent elevation of D-dimer rate at 26810ng/ml and fibrin/fibrinogen degradation products at 5.19 g/l, as well as over dosage in VKA with INR at 20, without abnormalities in platelet counts. COVID-19 pneumonia was confirmed by RT-PCR test and CT (Figure1) showed bilateral ground glass opacities (70% lung injury). Since the patient presented with abdominal pain, abdominal CT scan was performed, showing a non-obstructive abdominal aortic thrombosis: two pedunculated endoluminal thrombi based on parietal implantation at T9 and T11 stenosing the lumen by approximately 45-50% (Figure2), as well as large areas of splenic infarction (Figure3) and cortical lesions of the left kidney, suggesting renal infarction sites (Figure4). Patient was treated with therapeutic anticoagulation associated to aspirin, with a good initial result. One-month follow-up shows no complications.

Conclusion:

Our knowledge of this emerging human pathogen is rapidly progressing, and our understanding of management strategies to optimize outcomes in affected patients is evolving. This case supports the hypercoagulability state in COVID-19 and enhances the recommendation to use pharmacological prophylaxis of thrombosis.



Submission ID: 674

THE E-VITA OPEN PLUS PROTHESIS IN THE AORTIC ARCH AND DESCENDING AORTA SURGERY: FIRST CASE IN TUNISIA

sobhi mleyhi, Jalel Ziadi, Tesnim Besbes, Rim Miri, Mohamed Messai, Malek Ben Mrad, Raouf Denguir

University of Tunis El Manar, Faculty of medicine of Tunis, Cardiovascular surgery department, La Rabta Hospital, Tunisia

Background:

Aneurysms of the aortic arch extended to the descending thoracic aorta are particularly rare. The major evolutionary risk is rupture. Due to the high mortality of conventional surgery, several techniques were developed such as hybrid techniques.

Case report:

We present the case of a 62-year-old patient, presenting chronic chest pain. CT scan was performed showing 60 mm descending aortic aneurysm. Beginning at the level of the left subclavian artery and extended over 50 mm (fig 1). Given the recent recommendations and despite the fact that the technique has not been used in Tunisia before, our strategy is to choose hybrid treatment of the frozen elephant trunk using the prosthesis EVITA Open Plus. Under cardiopulmonary bypass and moderate hypothermia at 24°C; the first operative stage was aneurysm flattening under circulatory arrest: resection of the pathological part of the aorta and conservation of the origin of the supra-aortic trunks. Subsequently, the stented endoprosthesis part is introduced into the descending aorta in antegrade approach via a delivery system (fig 2). A suture of the intermediate sleeve, between the dacron prosthesis and the stent, with the aortic isthmus was performed (Fig3). After that, the supra-aortic trunks were reimplanted, followed by the proximal anastomosis on the ascending aorta (fig 4). Surgical follow-up was simple with a good angiographic result controlled at 1-month post-operative.

Conclusion:

Aortic aneurysm is a serious pathology with 0 to 11% mortality and 10 to 30% neurological complications. Open Evita plus technique seems encouraging alternative to open surgery. The success of this first case in Tunisia pushes to expand the indications of this technique.

Submission ID: 671

PERCUTANEOUS CORONARY INTERVENTION WITH BARE METAL STENTS IN THE AGE OF DRUG ELUTING STENTS; ASSESSMENT OF PRACTICES AND RESULTS IN TERMS OF IN-STENT RESTENOSIS

Saeb Ben Saad, Marwen Kacem, Mehdi Slim, Nouha Mekki, Housseem Thabet, Rim Letaief, Ayoub Meddeb, Sami Ouanes, Imen Ben Ali, Aymen Elhraiech, Rim Gribaa, Neffeti Elyes

Introduction:

Percutaneous coronary intervention (PCI) has become the standard of care in myocardial revascularization techniques. The use of drug eluting stents (DES) is currently the gold standard in PCI, thus limiting the use of bare metal stents (BMS). In Tunisia, the limited economic resources and indications of DES refund by health insurances both lead us to continue using BMS in a significant number of patients.

Aim:

To assess the results of PCI with BMS in terms of in-stent restenosis (ISR).

Methods:

We conducted a descriptive, single institution and a retrospective study between January 2006 and December 2016 including all the patients treated with PCI using BMS in the cardiology department of Sahloul Hospital in Sousse.

Results:

In total, 1174 PCI using BMS (1061 patients) were included. 232 cases of ISR were identified, i.e. a frequency of 19.76%. The mean time to the discovery of the ISR was 177.79 days (5.92 months).

The mean age of the patients who developed ISR was 61.93 ± 9.6 years, comparable to that of the group without ISR.

There is a significant relationship between stent size and the occurrence of ISR. Indeed, a diameter less than 3 mm is significantly associated with the occurrence of ISR ($p = 0.038$). Similarly, for a stent length exceeding 20mm. ($p = 0.032$).

Bivariate analysis identified diabetes and a stent length exceeding 20mm as independent factors of ISR.

The majority of patients who had an ISR underwent a second revascularization, which was at 62% (144) of cases a new PCI, using DES in 107 cases.

Conclusion:

Our study confirms the data in the literature by showing that PCI with BMS remains an important therapeutic option but grafted with a significant rate of ISR whose time to onset and risk factors are well identified.

Submission ID: 653

COULD P WAVE PEAK TIME PREDICT THE SEVERITY OF CORONARY ARTERY DISEASE IN PATIENTS WITH NON-ST SEGMENT ELEVATION MYOCARDIAL INFARCTION?

Emna Allouche, Asma Brahim, Habib Ben Ahmed, Mohamed Béji, Faten Elayech, Wejdène Ouechtati, Leila Bezdash

Hôpital Charles Nicolle, Tunisia

Background:

Severe coronary artery disease (CAD) is associated with a worsened prognosis in non-ST segment elevation myocardial infarction (NSTEMI) patients. Depending on the severity of CAD, there may be a prolongation of atrial depolarization time as a result of left ventricular dysfunction and atrial ischemia. In our study, we aimed to evaluate whether the P wave peak time (PWPT) in the electrocardiography (ECG) obtained during the diagnosis in NSTEMI patients, could predict the severity of CAD.

Methods:

We retrospectively reviewed the medical records of patients admitted to the cardiology ward of Charles Nicolle's Hospital of Tunis with NSTEMI. The coronary angiography records of all patients were analysed and SYNTAX scores were calculated. Patients were divided into two groups, according to CAD severity. The first standard 12 lead ECG was analysed for each patient. The time from the beginning of the P wave to its peak was defined as PWPT, it was measured in the leads DII and V1.

Results:

The PWPTs in the leads DII and V1 were longer in the group with severe CAD (66.1 ± 12 vs. 57.8 ± 11 ms, $p=0,018$, 62 ± 15 vs. 58 ± 14 ms, $p=0,345$ respectively). Only PWPT in DII was significant. PWPT in DII was found to be an independent predictor of severe CAD and the best cut-off value of PWPT in the lead DII was 58.5ms with a sensitivity of 71.4% and a specificity of 48.9%.

Receiver operating characteristic (ROC) curve analysis to determine the optimal cut-off value of the P wave peak time (PWPT) in the lead DII for prediction of severe coronary artery disease (CAD).

Conclusion:

This study results suggested that prolonged PWPT in the lead DII is associated with severe CAD. The diagnosis of CAD severity using non-invasive tools as the ECG which is accessible and applicable in all patients could be useful for patient management.

Submission ID: 657

CATASTROPHIC EMBOLIC COMPLICATIONS IN A PATIENT WITH LEFT VENTRICULAR NON-COMPACTION

Emna Allouche, Mariem Mediouni, Malek El Arbi, Faten Boudiche, Mohamed Béji, Wejdène Ouechtati, Habib Ben Ahmed, Leila Bezdah
 Cardiology Department, Charles Nicolle's Hospital

Introduction:

Left ventricular non-compaction (LVNC) is a rare congenital heart disease. Diverse clinical manifestations were reported to range from no symptom to the development of heart failure, arrhythmias, systemic embolic events, or sudden cardiac deaths.

Case presentation:

A 39-year-old non-smoker man presented to the emergency department with prolonged chest pain and ECG changes showing an acute inferior myocardial infarction. Vital signs on admission were normal. He had no neurological impairment.

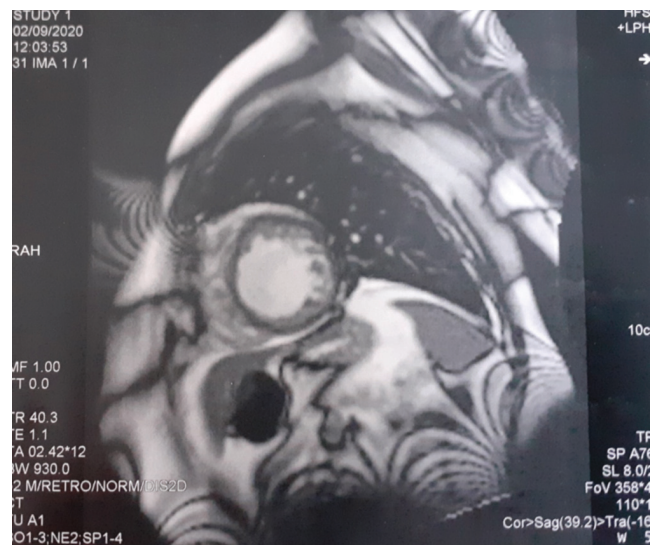
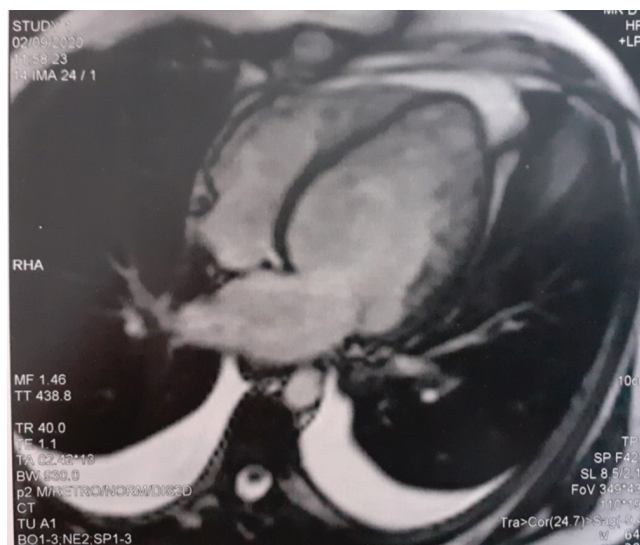
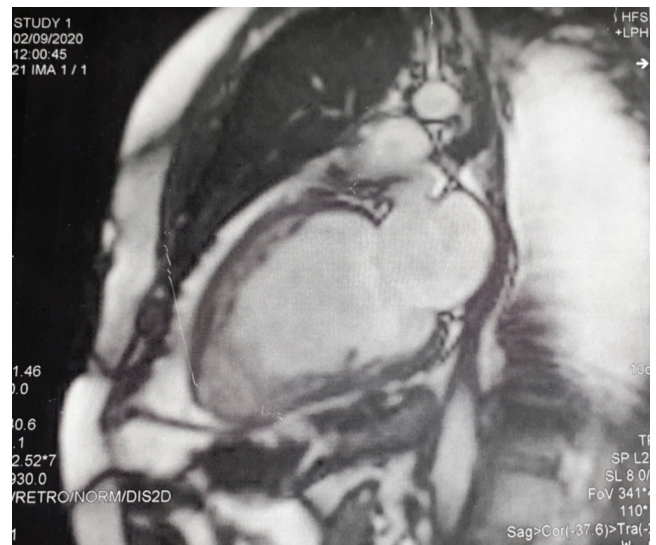
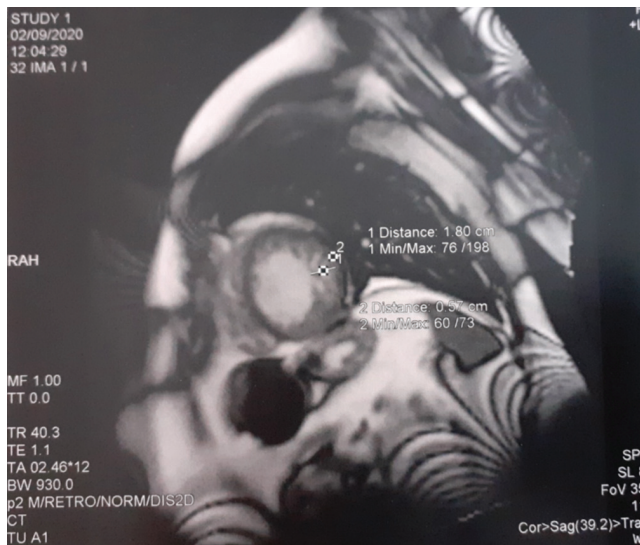
We opted for a non-invasive reperfusion strategy because primary PCI could not be performed in a timely manner.

Later, the patient admitted that he had a complaint of progressive dyspnoea for two months. A week prior to this episode, he underwent two-dimensional echocardiography showing an enlarged left ventricle (LV) with severe LV dysfunction (EF 15%). Cardiac magnetic resonance imaging (CMRI) confirmed the LV enlargement and the reduced EF and showed prominent trabeculations and deep intertrabecular recesses with a thinner compact epicardial side in LV apex and lateral wall with non-compacted/compacted ratio > 2.3. There were multiple small thrombi within the trabeculations of the inferior and anterior walls, and a small contrast enhancement in the apical segment of the inferior wall strongly suggesting an ischemic origin probably embolic (Figures 1, 2, 3 and 4). These findings were consistent with LVNC cardiomyopathy diagnosis.

He was transferred to the ICU and before activating the Cath-lab, he complained of a visual blur. A first head computed tomography was normal. A second CT scan was performed 3 hours later (due to persistent headache) and revealed a recent ischemic stroke in the left posterior cerebral artery territory, a haemorrhagic stroke in the right posterior cerebral artery territory, and tri-ventricular hydrocephalus. The patient was intubated and submitted to mechanical ventilation for neurological distress. He was on Mannitol and a decompressive craniotomy was indicated but he died quickly after.

Conclusion:

Prominent myocardial trabeculae and deep recesses along with LV dysfunction can cause stagnant blood flow, which can result in thrombus formation causing coronary and cerebrovascular embolization which was the case of our patient.



Submission ID: 666

PERCUTANEOUS CORONARY INTERVENTION WITH ROTATIONAL ATHERECTOMY: IMMEDIATE AND LONG-TERM RESULTS

BOUDICHE SELIM, RAJHI MONOOM, REKIK BASSEM, ZOUARI FOURAT, OUALI SANA, MGHAIETH FATHIA, FARHATI ABDELJELIL, BEN HALIMA MANEL, MOURALI MOHAMED SAMI

LA RABTA HOSPITAL, TUNISIA

Background:

Severely calcified coronary lesions, whose prevalence among patients referred for percutaneous coronary intervention (PCI) is 6%, represent a real challenge. The purpose of our study was an evaluation of practices of PCI with Rotational Atherectomy (RA) in terms of immediate and long-term safety and efficacy.

Methods:

A single-center prospective observational "all-comers design" study over a four-year period from January 2014 to December 2017, including all patients who benefited from PCI with RA for de novo calcified lesions. Primary endpoint was composite of major adverse cardiac events (MACE) at 12-month minimum follow-up.

Results:

51 consecutive patients were included. An increasing AR activity representing up to 4.8% of the total PCI volume during the last year of the investigated period was observed. Mean age was 69.3±9.8 years. Sex ratio was 4. A high prevalence of diabetics and hypertensives was noted (62.7% and 60.8% respectively). Chronic renal failure and hemodialysis accounted for 15.7% and 5.9% of patients respectively. 76.5% of the patients had multivessel disease. A total of 70 lesions were treated by AR. Left anterior descending and left main were the most frequently treated sites, followed by right and circumflex coronary arteries (82.3%, 23.5%, 17.6% and 13.7% of patients respectively). Drug eluting stents were exclusively used in 86.2% in target lesions. Immediate procedural success was achieved in all patients. Only one procedural complication (1.9%) was recorded (complete atrioventricular block related to septal branches embolization requiring definitive cardiac stimulation). After median follow-up of 17.0 months [12.0-20.0], which was effective for all patients, MACE rate was 19.6%. The cardiac mortality was 5.9%. Clinically driven target lesion and vessel revascularizations were 3.9% and 7.8%, respectively, motivated by in-stent restenosis in all cases. No definite or probable thrombosis was reported. A Syntax Score II for ICP strategy ≥40 was the only independent predictor of long-term MACE occurrence in multivariate Cox regression analysis.

Conclusions:

In our study, PCI with RA in heavy calcified lesions appears to be a safe and effective tool. The long-term MACE rate, while comparable to real-life registries, remains quite significant and appears to be largely linked to patients' comorbidities rather than the technique itself. This rate can be predicted by the SYNTAX Score II for ICP strategy.

Submission ID: 648

PERCUTANEOUS ANGIOPLASTY OF THE PROFUNDA FEMORIS ARTERY: A SAFE AND EFFECTIVE ENDOVASCULAR TECHNIQUE

Ben Mrad Melek, Mlayhi Sobhi, Fourati Malek, Miri Rim, Derbel Bilel, Denguir Raouf

Cardiovascular Surgery Department, Rabta Hospital, Tunis, Tunisia

Introduction:

The limb with an occluded superficial femoral artery (SFA) relies on the Profunda collaterals for adequate perfusion. Frequently the Profunda is also diseased exacerbating the limb ischaemia

We present in this case an angioplasty of the Profunda artery in a patient suffering from severe ischemia of the lower limb.

Observation:

We report the case of a 61-year-old patient with diabetes, hypertension, dyslipidaemia, admitted to our department for severe critical ischemia of the left lower limb with ulcer of the fifth toe; a CT angiography of the lower limbs showed long stenosis of the superficial femoral artery, associated with a short occlusion of the Profunda, the popliteal artery was occluded without runoff in the foot. First, we dilated the superficial femoral artery with a 5 * 60mm "Evercross" balloon (Medtronic) and then dilated the Profunda with a 3 * 40mm "Admiral" (Medtronic) balloon with a good angiographic result.

The clinical course was favourable with reduced pain and healing of the ulcer.

Discussion:

Profunda angioplasty may be the only treatment option in elderly patients suffering from critical ischemia of the lower limb, related to occlusion of the femoro-popliteal axis associated with poor runoff. It offers the possibility of relieving resting pains and facilitating the healing of ulcers.

It can be performed by antegrade puncturing the common femoral artery or by using the crossover technique to treat proximal lesions.

Conclusion:

We thought that Profunda femoral artery angioplasty could be performed with a high rate of technical success and low risk of intervention.

The quantification of the contribution of this atypical angioplasty of in the overall clinical improvement is difficult to determine, but it is responsible for a large part.

Submission ID: 681

PREDICTORS OF MORTALITY AND REHOSPITALIZATION IN ACUTE CORONARY SYNDROMES WITH LEFT BUNDLE BRANCH BLOCK

Triki Zied, Azaiez Fares, Hentati Rim, Testouri Emna, Tlili Rami, Tlili Rami

CHU Mongi Slim, Tunisia

Introduction:

The occurrence of a new or presumed new left bundle branch block (LBBB) associated with clinical signs of myocardial ischemia is considered to be a very high risk acute coronary syndrome (ACS) requiring rapid intervention. The prognosis of these patients remains poorly understood. In our study, we established the predictive factors of mortality and re-hospitalization after revascularization.

Methods:

This was a longitudinal, retrospective and descriptive study including 70 patients hospitalized in the cardiology department of Mongi Slim Hospital for a suspected ACS with a complete LBBB. The predictive factors of mortality and re-hospitalization were evaluated by clinical, laboratory, electrical and imaging (echocardiography) data from patients during hospitalization and long-term follow-up.

Results:

We included 70 patients in our study. The mean age of the patients was 63.4 years, predominantly male. Mortality factors statistically significant in univariate analysis were: Age > 65 years, smoking, diabetes and chronic renal failure. In multivariate analysis, statistically significant factors were also age > 65 years, male sex, hypertension, renal failure and multivessel coronary artery disease.

The statistically significant factors associated with readmissions in univariate analysis were: Age ≥ 50 years, family history of cardiovascular disease, personal history of coronary artery disease, chronic renal failure and multivessel coronary artery disease. In multivariate analysis, statistically significant factors were also Age ≥ 50 years, male sex, impaired left ventricular ejection function, multivessel coronary artery disease and percutaneous coronary intervention.

Conclusion:

The occurrence of a complete LBBB during ACS worsens the disease prognosis. Age, cardiovascular risk factors and multivessel coronary artery disease are the most important predictors of mortality and re-hospitalization. Therefore, rapid and effective management with good follow-up can improve the prognosis.

Submission ID: 698

IN-HOSPITAL MORTALITY PREDICTORS OF SURGICAL TREATMENT OF INFECTIVE ENDOCARDITIS

Sobhi Mleyhi, Mohamed Messai, Rim Miri, Imtinene Ben Mrad, Yahia Dahmani, Skander Ben Omrane, Melek Ben Mrad, Raouf Denguir

University of Tunis El Manar, Faculty of Medicine of Tunis, La Rabta Hospital, Tunisia

Background:

Infective endocarditis still have high morbidity and mortality. Surgical treatment is an integral part of the treatment protocol in some cases. Our objective is to detect predictive factors of morbidity and mortality in operated patients.

Methods:

It's a monocentric and retrospective study including 154 patients were operated on for infective endocarditis between January 2004 and December 2016. Clinical, paraclinical and therapeutic data have been collected and analysed by SPSS 21.0.

Results:

The mean age was 41 ± 25 years with sex ratio of 2.1. Infective endocarditis was secondary to a pre-existing valve disease in 71%, mainly represented by rheumatic valve disease in 45% of cases and degenerative valve disease in 9%. The main locations were aortic and mitral valves with aortic insufficiency in 33% of cases, mitral regurgitation in 28% of cases, mitral stenosis in 9% of cases aortic stenosis in 6% of cases, and tricuspid insufficiency in 4% of cases. However, it occurred on valve prosthesis in 32 patients (21%). Microorganism was identified in only 46,7% of cases; streptococci and staphylococci were the most frequent and the gateway to infection in half of the cases. Left ventricular function was low in 29.4% of cases.

The indication for surgery was hemodynamic in 56 cases (36%), infectious in 78 cases (50.6%) and embolic in 20 cases (13.4%). The operating time, from the diagnosis of IE, was 16.2 ± 8.6 days. Valve replacement was performed in 75.9%, while 24.1% of cases had valve repair. In-hospital mortality was 10,6%. In multivariate analysis, pre-operative hemodynamic shock (OR=2.8; p=0.036) and annular abscess (OR=1.7; p=0.042) were independent predictors of in-hospital mortality.

Conclusion:

Infective endocarditis is a progressive disease, hence the importance of regular epidemiological studies. The current trend is for earlier surgery favouring valve repair.



Submission ID: 732

A COMPARATIVE STUDY: POSTOPERATIVE RESULTS OF BLALOCK TAUSSIG SHUNTS ACCORDING TO THE UNDERLYING HEART DISEASE AND THE AGE OF THE CHILD

Housseem Thabet, Marwen Kacem, Ayoub Meddeb, Imen Mgarrech, Nabil Ajmi, Safa Dardouri, Rim Gribaa, Mehdi Slim, Imen Ben Ali, Saeb Ben Saad, Amin Tarmiz, Chokri Kortas, Elyes Neffati, Sofien Jerbi

Service de Cardiologie, hôpital universitaire, Sahloul, Sousse, Tunisia

Introduction:

Since its introduction in 1945, the Blalock-Taussig (BT) shunt has become the first-line palliative surgery performed in children with cyanogenic congenital heart disease by tight obstacle in the pulmonary pathway.

Materials and methods:

This was a descriptive and retrospective study carried out in the cardiovascular and thoracic surgery and cardiology department at the Sahloul Hospital in Sousse over a period of time from 1998 to 2017. We included in our study all children under 18 who had been operated for a BT-type palliative shunt in the CVTS department of the Sahloul hospital, regardless of the indication for the shunt.

Results:

136 cases were re-identified. The median age at the time of the first BT shunt surgery was 93.5 days. 35 patients (25.7%) were newborns, 96 (70.6%) were infants, and only 5 (3.7%) were children. In our series, we noted a male predominance: 77 boys (56.6%). All patients were carriers of cyanogenic congenital heart disease with obstruction in the right pathway. The heart disease most often operated on was open septal pulmonary atresia (OSPA): 38 cases (27.9%), followed by tetralogy of Fallot (TF) (24.3%), and ISPA in 10.3%. Heart disease was complex in 30.9% of cases. The age at the time of surgery for OSPA was significantly lower than that of TF with a mean age for OSPA of 68.55 days against a mean age of 253.82 days for the TF, $p = 0$. A "BT shunt diameter / weight" ratio > 1 was significantly more present during surgery for OSPA (73.8%) compared to 26.2% during TF, $p = 0$. The postoperative mortality rate was significantly higher during surgery for OSPA with 57.7% of deaths versus 22.4% of deaths for TF, $p = 0.022$. The times to intervention in newborns and infants were significantly different. In fact, the operation was performed urgently (≤ 48 h) in 85.7% of cases in newborns while it was performed cold (> 48 h) in 79.5% of cases in infants, $p = 0$. Indeed 1.6% of patients with a ratio < 1 were newborns against 98.4% who were infants, $p = 0$. The length of hospital stay in postoperative

intensive care was significantly higher in infants with a median at 3 days than in newborns with a median of 1.8 days $p = 0.04$. The total postoperative hospital stay was significantly higher in infants with a median of 2.1 days than in newborns with a median of 1.1 days $p = 0$. Regarding mortality, there was no significant difference between the two age groups.

Conclusion:

This palliative surgery has become common practice in our country, it has saved lives.

Submission ID: 689

ACUTE ST-SEGMENT ELEVATION MYOCARDIAL INFARCTION AND CARDIAC ARREST AS FIRST CLINICAL MANIFESTATION OF ESSENTIAL THROMBOCYTHEMIA

Lagha Elyes, Azaiez Fares, Hentati Rim, Testouri Emna, Tlili Rami, Ben Ameer Youssef

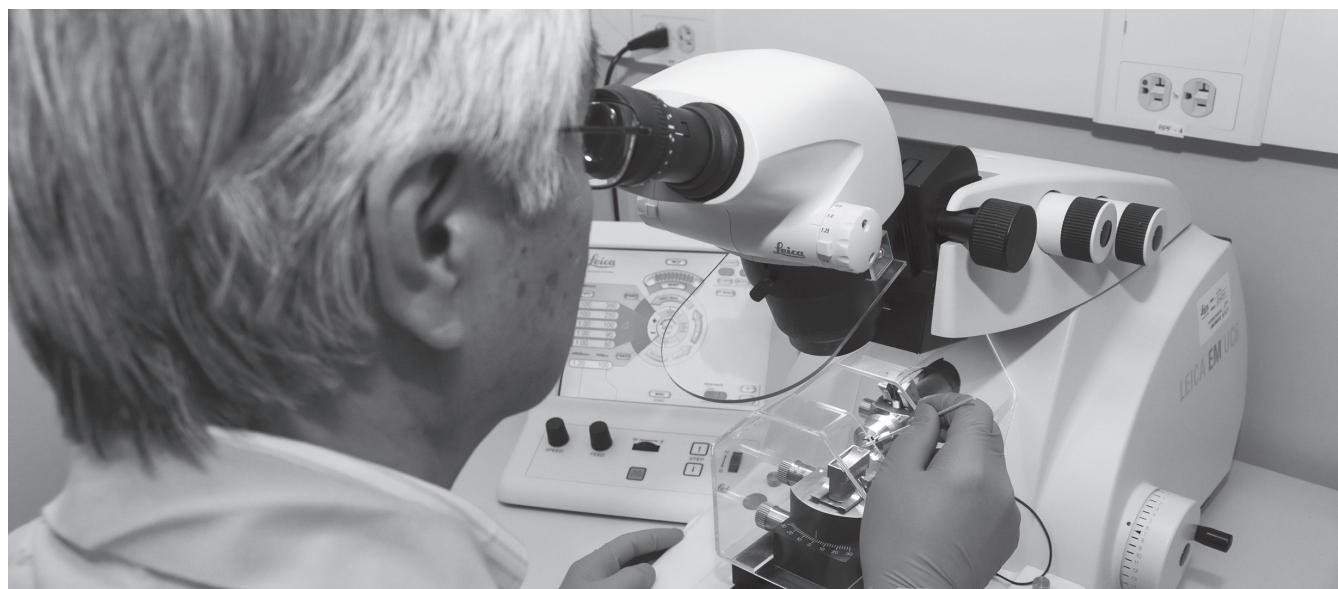CHU Mongi Slim, Tunisia

Introduction:

Essential thrombocythemia (ET) is a myeloproliferative neoplasm characterized by abnormal proliferation of the megakaryocytes in the bone marrow and sustained elevation of platelet count in the peripheral blood (Platelets $\geq 450 \times 10^9/L$). Thrombosis in the cerebral, coronary, and peripheral arteries is the major cause of morbidity and mortality in patients with ET. In the medical literature, just few cases of acute myocardial infarction have been reported in association with ET. We report an infrequent case of ST-segment elevation myocardial infarction (STEMI) as the first clinical presentation of a previously undiagnosed ET.

Clinical case:

A 30-year-old man with no past medical history presented to the emergency unit reporting chest pain. He reported no history of cardiac problems, was not taking any cardiac medications and he denied smoking, alcohol or illicit drug use. A 12-lead electrocardiogram revealed sinus tachycardia associated with ST-segment elevation and Q waves in the anterior and lateral leads. Atrial and ventricular extrasystoles were also noted [Figure 1]. Five minutes later, the patient presented ventricular fibrillation which was resuscitated by an external electrical shock. The patient underwent urgent coronary angiography, revealing an acute occlusion of proximal left anterior descending coronary

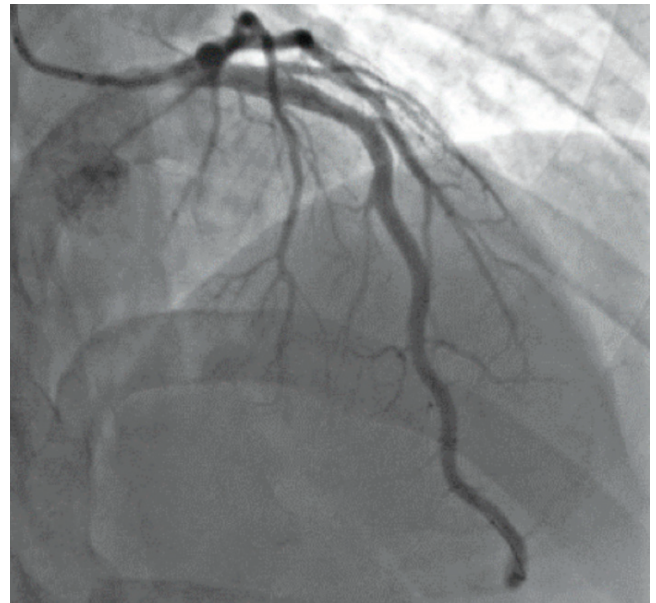
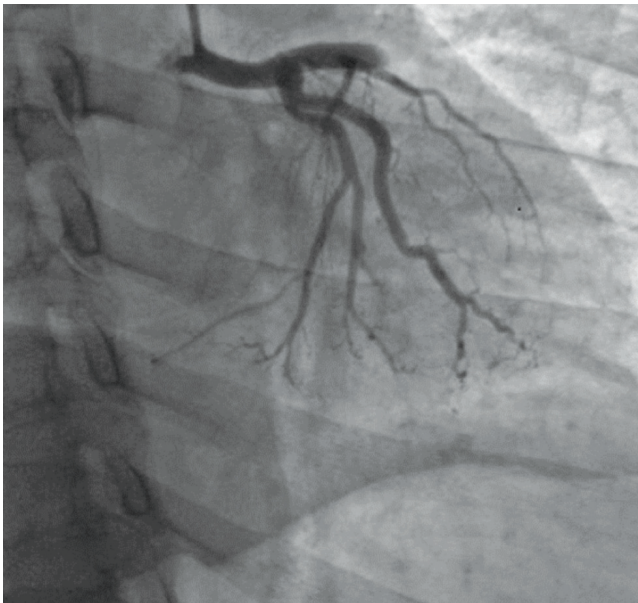
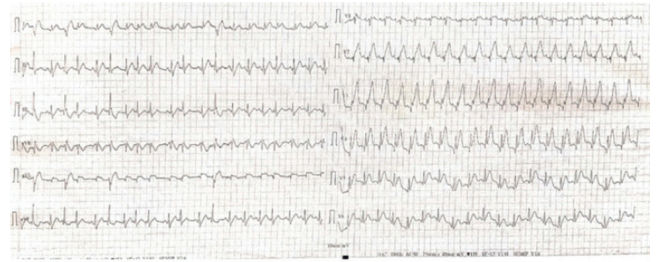


artery (LADA) with TIMI 0 flow [figure2]. A Bare metal stent was successfully implanted in the proximal LADA [figure3]. Blood tests revealed severe thrombocytosis with 1220×10^9 platelets /l, which persisted after 3 months. The patient was evaluated by the hematology team and had a bone marrow aspiration and biopsy. ET was confirmed by positive JAK2-V617F mutation, negative BCR-ABL1 translocation, and compatible bone marrow biopsy [Figure4]. Treatment with cytoreductive therapy was instituted to lower the platelet count in addition to aspirin and clopidogrel.

Conclusion:

Myocardial infarction as first clinical manifestation leading to the diagnosis of ET is infrequent. Our case emphasizes the importance of pursuing the investigations in patients presenting

with STEMI and high platelet counts. We recommend to keep these patients under double antiplatelet therapy for a prolonged period.



Submission ID: 692

ATHLETE'S HEART: ENDURANCE VERSUS RESISTANCE EXERCISE TRAINING

Dardouri Safa, Sihem Hraiech, Imen Bouhlel, Imed Laatiri

Farhat Hached Hospital Cardiology Department, Tunisia Sousse

Background:

Regular physical activity, including intensive training and high-level competitions, can induce cardiac morphological changes known by the name of "athlete's heart".

Aim:

the objective of our study was to evaluate a possible correlation between the modifications induced according to the type of sport discipline (endurance versus resistance) on left ventricular structure and function and their impact on cardiac performance during exercise.

Materials and Methods:

It was a comparative descriptive study between two groups of young athletes practicing two different disciplines. Ten high-level athletes (5 endurance and 5 resistance) received a resting Transthoracic echocardiography to analyze morphological parameters followed by an exercise stress test with increasing load.

Results and Discussion:

Two groups were comparable in terms of sex, age and height. Echocardiographic analysis found a greater left ventricular diameter in the enduring than that of the resistant training athletes. The latter have thicker walls without there being any significant difference between these two groups. The systolic function was comparable between the two groups while the diastolic function was slightly better in the endurance group. Resting and peak heart rates were slightly lower in endurance people. For the stress test, the peak oxygen consumption (O₂max) and the maximum aerobic power were increased in the enduring training athletes compared to the resistant (69.02 ± 7.18 versus 50.38 ± 5.98 ml / min / kg, $p < 0.05$) for the peak oxygen consumption (O₂max) and respectively (305.3 ± 65.5 versus 242.5 ± 25.1 W, NS) for maximum aerobic power. Maximum workload was independently and positively associated with LV tele diastolic diameter only in endurance trained athletes.

Conclusion:

participation in regular and intensive sports may lead to an increase in LV wall thickness and chamber size. These changes emerge in different sizes and shapes according to the type of exercise.

Submission ID: 693

COR TRIARIATUM SINISTRUM WITH SINUS VENOSUS ATRIAL SEPTAL DEFECT AND PARTIAL ANOMALOUS PULMONARY VENOUS RETURN IN A NEWBORN: ABOUT ONE CASE

Dardouri Safa, Imen Ben Ali, Elhraich Aymen, Slim Mahdi, Gribaa Rim, Naffeti Ilyess

Sahloul Hospital

Background:

Cor triatriatum Sinistrum is a rare congenital cardiac anomaly defined by an abnormal septation within the left atrium leading to inflow obstruction to the left ventricle. It exists either in isolated classical form or may be associated with simple to complex congenital cardiac anomalies.

Aim:

Keep in mind such diagnosis in the face of cardiorespiratory distress in a newborn.

Case Report:

We report the case of a newborn female hospitalized at 18 days of her life in the neonatal department for the management of acute cardiorespiratory distress requiring the use of nasotracheal intubation.

She was born from a monofetal pregnancy well followed, with delivery at term and by vaginal route without incidents. There was no notion of perinatal suffering. On admission, congestive heart failure with pulmonary edema was present. Chest x-ray revealed cardiomegaly (cardiothoracic ratio = 0.67) with signs of pulmonary congestion. The electrocardiogram showed right atrial enlargement and right ventricular hypertrophy. Two-dimensional echocardiography clearly demonstrated cor triatriatum Sinistrum, sinus venosus atrial septal defect, Partial anomalous pulmonary venous return and pulmonary hypertension. Patient underwent excision of the membrane and repair of associated Cardiac defects simultaneously.

Discussion:

Cor triatriatum is a rare congenital heart defect which can present at any age depending upon the presence of associated cardiac anomalies and the size of communication between the common chamber and the left atrium. Clinical presentation is dependent on the degree of functional pulmonary venous obstruction and the presence of associated congenital cardiac lesions. When the communication between the pulmonary venous chamber and the left atrium is small (<3 mm), almost 75% of the patients die in infancy if left untreated.

Conclusion:

Cor triatriatum can present as an isolated lesion or more commonly with associated cardiac lesions with ASD being the most common defect followed by pulmonary venous anomalies and left Superior vena cava.

Submission ID: 702

OXYGEN DELIVERY MONITORING UNDER CARDIOPULMONARY BYPASS: WHAT IMPLICATION ON POSTOPERATIVE MORBIDITY AND MORTALITY?

BOUSNINA Mouna, JEMEL Amine, NAFFETI Dhia, SENDI Tarak, SOUMER Khedija, OUERGHI Sonia, DRIDI Amira, MESTIRI Tahar, MARGHLI Adel

Department of Thoracic and cardiovascular surgery Abderrahmen Mami HOSPITAL, Tunisia

Department of Anaesthesiology Abderrahmen Mami HOSPITAL, Tunisia

Introduction:

The standard control parameters of cardiopulmonary bypass (CPB) currently used in Tunisia are replaced in Western countries by the concept of "goal-directed-perfusion" requiring oxygen delivery (DO₂) minimum at 270ml / min / m². In this study, we explored the association between the DO₂ and the postoperative morbidity and mortality.

Methods:

This is a cross-sectional and retrospective observational study including a series of 50 patients operated on for myocardial revascularization under CPB.

Results:

We noticed a significant correlation between starting DO_{2i} and Creatinine clearance at day 0, Δcreate (day 1-day 0) and ventilation time. There was also a significant correlation between discharge DO_{2i} and daytime urine output, ventilation time, hospital stay and in-hospital mortality. Through a univariable study, we compared the classic parameters of perfusion monitoring during CPB in addition to the starting DO_{2i} with the different postoperative results. It was noted that the starting DO_{2i} figures below the threshold of 270ml / min / m² were significantly correlated with the duration of administration of catecholamines postoperatively, with prolonged ventilation, with the variation in serum creatinine postoperatively and with in-hospital mortality.

Conclusion:

DO₂ is a monitoring tool that has proven its advantages for monitoring under CPB.

Submission ID: 728

POST-OPERATIVE MORBI-MORTALITY OF SURGICAL MYOCARDIAL REVASCULARIZATION WITH A SINGLE DOSE OF WARM BLOOD CARDIOPLEGIA

Amine Jemel, Kais Ben Rejeb, Tarek Sendi, Mouna Bousnina, Khedija Soumer, Chaker Jaber, Adel Marghli
Abderrahmen Mami Hospital, Tunisia

Introduction:

Different techniques are used for myocardial protection during multiple arterial revascularizations, but there is no clear recommendation regarding which one to prioritize; and the impact of these techniques on postoperative evolution of the patient's is not studied.

The objective of this work is to assess the impact of using a single dose of warm blood cardioplegia associated with intermittent infusion of potassium-free blood through grafts used in multiple arterial surgical myocardial revascularization on the hospital morbi-mortality and determine the predictors of morbidity-mortality after this type of intervention.

Methods:

Our study is retrospective, evaluative, cross-sectional in the cardiovascular and thoracic surgery department at Abderrahmen Mami Hospital Ariana between January 1, 2018 and June 30, 2019, including coronary artery bypass surgery patients with at least one revascularized coronary artery using an arterial graft with warm blood cardioplegia in mono-antegrade dose combined with intermittent infusion of potassium-free blood through the used grafts.

Results:

In our study, the average age was 60 ± 8 years. The sex ratio was 5.2 with male predominance. Tobacco was the primary coronary risk factor (80%), followed by diabetes (61.2%), high blood pressure (54.1%), dyslipidemia (44.7%), and obesity (27.1%).

Acute ST (-) coronary syndrome was the most common (75.3%). Coronary angiography revealed tritroncular involvement in 74.1% of cases, tritroncular with the left trunk involvement in 3.5% of cases, bi-truncated in 16.5% of cases and mono-truncated in 5.9% of cases.

The average LVEF was $55 \pm 10\%$.

The Euroscore II average was 1.14 ± 0.76 .

In intraoperative, the average duration of CEC was $72.75 \text{ minutes} \pm 27$ (22 min-180 min) and that of aortic clamping was $52.79 \text{ minutes} \pm 17$ (16 min-93 min).

In intraoperative, we noted the occurrence of rhythm disorder (atrial fibrillation) in 4 patients (4.7%), with a higher prevalence in males ($p=0.04$ and $OR=6.3$) and we had 2 deaths due to LV dysfunction (2.4%), with as predictors female sex ($p=0.003$ and $OR=2.1$), a higher Euroscore II ($p=0.049$ and $OR=4.8$), and the presence of intraoperative complication ($p=0.014$ and $OR=10.27$).

The average extubation time was $9.3 \pm 12 \text{ h}$ (3-48)

Withdrawal from catecholamines was easy for 72 patients (84.7%) and difficult for 13 patients (15.3%). Elevated troponin levels at H24 ($p=0.004$), low LVEF ($p=0.011$), and the presence of segmental kinetics disorder ($p=0.03$).

Submission ID: 721

MYOCARDIAL REVASCULARIZATION SURGERY AFTER PERCUTANEOUS CORONARY DILATION: RESULTS OF A TUNISIAN BICENTRIC STUDY

Jihen MAALEJ

Department of thoracic and cardiovascular surgery, Abderrahmen Mami hospital, Tunisia

Background:

Despite therapeutic advances, the results of coronary surgery in patients with a history of angioplasty show a trend towards early excess morbidity and mortality. The aim of our study was to describe the short and medium term postoperative morbidity and mortality of myocardial revascularization surgery in patients with a history of coronary angioplasty and we brought out the predictive factors of mortality in these patients.

Methods:

It was a bi-centric descriptive retrospective study UHC of Sousse and UHC of Ariana including a sample of patients with a history of coronary angioplasty, operated on for surgical revascularization of the myocardium between September 1, 2017 and September 31, 2019. Pre, per and postoperative data were collected and analyzed by SPSS 25.0 software.

Results:

The majority of patients required the use of pharmacological supports (65.6%). The most prominent pulmonary complication was the occurrence of pneumonia (68.8%). The most frequent cardiogenic complications: the use of catecholamine for more than 24 hours (23.4%), acute edema of the cardiogenic lung (21.9%), myocardial infarction (4.7%) and recurrence postoperative angina (1.6%). Death was encountered in 12.5% of patients and the cardiogenic cause was the most common (75%). Univariate analysis was able to conclude that hypertension ($p = 0.043$) and advanced age ($p = 0.003$) were preoperative predictors of mortality.

Intraoperatively, complete revascularization was significantly correlated with the survival rate with $p = 0.011$. Transfusion ($p = 0.131$), and prolongation of cardiopulmonary bypass ($p = 0.018$) were also predictors of mortality. Postoperatively, the occurrence of myocardial infarction ($p = 0.001$) and reintubation ($p = 0.001$) were predictive factors of mortality. Also, patients with sleep apnea syndrome had more acute pulmonary edema postoperatively with $p = 0.030$ and tobacco was a predictive factor for the occurrence of infectious lung disease postoperatively with $p = 0.002$. A multivariate analysis allowed us to retain as predictive factors of death from any cause, reintubation ($p < 10^{-3}$) and postoperative myocardial infarction ($p < 10^{-3}$).

Conclusion:

Patients with a history of coronary angioplasty show a higher mortality, the more so when the revascularization is incomplete and the rates of myocardial infarction and postoperative reintubation are high.

Submission ID: 729

PROGNOSTIC FACTORS OF MEDIASTITIS, SINGLE-CENTER STUDY OF 39 CASES AND REVIEW OF THE LITERATURE.

Houssef Thabet, Marwen Kacem, Ayoub Meddeb, Imen Mgarrech, Nabil Ajmi, Saeb Ben Saad, Rim Letaief, Rim Gribaa, Mehdi Slim, Imen Ben Ali, Taieb Cherif, Amin Tarmiz, Chokri Korats, Elyes Neffati, Sofien Jerbi

Service de Cardiologie, hôpital universitaire, Sahloul, Sousse, Tunisia

Introduction:

Mediastinitis, a deep infection of the surgical site, is a serious and rare infectious complication of cardiac surgery, the occurrence of which concerns 1 to 3% of surgeries by sternotomy. In fact, it is a nosocomial infection which increases the length of hospital stay, and it is associated with an excess mortality in patients undergoing cardiac surgery.

Patients and methods:

This is a retrospective, descriptive study carried out in the cardiovascular and thoracic surgery and cardiology department of CHU SAHLOUL in Sousse. We included patients who underwent revision surgery for mediastinitis between 2013 and 2018. We adopted the criteria proposed by "Centers for Disease Control and Prevention" or CDC to retain the diagnosis of mediastinitis.

Results:

Out of 1111 cardiac surgery procedures performed during the study period, 39 patients were recovered for mediastinitis, for an overall incidence of 3.5%. In our study population, 64% of mediastinitis occurred in men, the mean age was 66.41 years \pm 9.187 years. A body mass index $>$ 25 (obese) was found in 84.6% of patients. Preoperative hypertension, diabetes and NYHA Stage II were found in 71.8%, 69.2% and 53.8% of patients, respectively. At the time of the study, smoking was noted in 13 patients. In our series, the mean length of preoperative stay was 11.05 days \pm 9.127 days. Mediastinitis occurred in 79.5% of patients operated on for coronary bypass surgery and in 48.4% of cases the removal was from both internal mammary arteries. Deep infection of the median sternotomy was found in 84.6% of patients whose duration of CEC was less than 120 min, 86.8% of them stayed in intensive care for more than 48 hours and 92, 3% received mechanical ventilation for less than twenty-four hours. Gram-negative bacilli were demonstrated in 20.5% of cases of mediastinitis with four cases of pseudomonas aeruginosa. The mean time to onset of mediastinitis in our study population was 22.49 days \pm 18.33 days with 94.4% of cases occurring beyond seven days.

Conclusion:

Mediastinitis remains a serious complication after cardiac surgery, by knowing the risk factors one can act on it early and prevent morbidity and mortality secondary to mediastinitis.

Submission ID: 569

DIABETIC AND NONDIABETIC PATIENTS WITH ACUTE CORONARY SYNDROME: WHAT ABOUT THE DIFFERENCES?

Ben Hlima Manel, Yaakoubi Wael, Boudishe Slim, Mghaith Fathia, Rekik Bassem, Laarbi Noureddine, Farhati Abdejilil, Murali Med Sami

RABTA Hospital, Tunisia

Objectives:

The aim of this study was to determine characteristics of diabetic patients in acute coronary syndrome and to compare them to non-diabetic patients.

Methods:

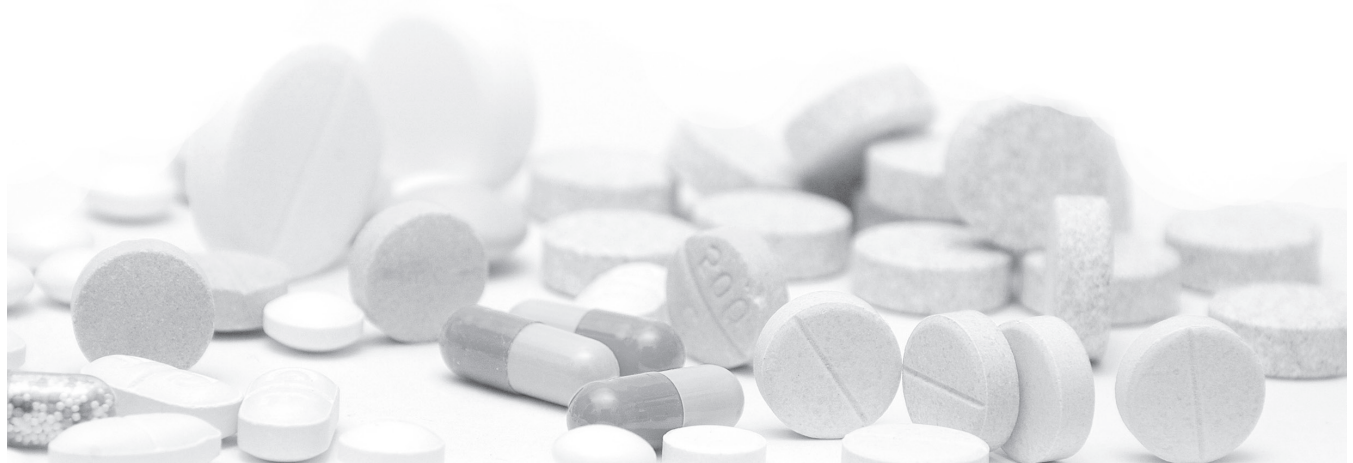This is a prospective observational study of 404 patients consecutively admitted for ACS. Baseline characteristics were compared for diabetic and non-diabetic patients.

Results:

We enrolled 404 patients (diabetics = 174; 43%) with mean age of 60 \pm 10 years (diabetics 60 \pm 10, nondiabetics 59 \pm 10). There were significantly less of men and more women in diabetics (men: 73% vs 82%; women: 27% vs 17%; $p=0,02$). STEMI and NSTEMI had comparable distribution between diabetics and non-diabetics: STEMI (52% vs 55%; $p=ns$) and NSTEMI (47% and 44%; $p=ns$). Among diabetics versus nondiabetics there was greater prevalence (%) of hypertension (59% vs 38%; $p= 0,001$), dyslipidaemia (35% vs 14%; $p=0,001$), and lower prevalence of smoking/tobacco use (64% vs 77%; $p=0,003$). Diabetics have greater comorbidities: chronic heart failure (12% vs 5%; $p=0,02$), ischemic cardiopathy (24% vs 13%; $p= 0,006$) and stroke (8,6% vs 3,9%; $p=0,046$). In STEMI 78 patients (35%) were thrombolysis (diabetics:38% vs non-diabetics 33%), percutaneous coronary interventions (PCI) was in 67% diabetics versus 66% nondiabetics and coronary bypass surgery in 12% versus 7% ($p=0,02$). During hospitalization; diabetics had frequently as mainly MACE: left cardiac heart failure (11% vs 5%; $p=0,02$). There were more diabetics patients with a KILLIP \geq 2 (12% vs 5%; $p=0,013$). At angiography: diabetics had higher prevalence of three coronary artery disease (32% vs 16%; $p<0,001$) and less prevalence of only one coronary artery disease (36% vs 47%; $p=0,032$). At echocardiography, diabetics had mainly a lower ejection fraction (45% vs 50 %) besides all other parameters were similar.

Conclusions:

Diabetic patients with ACS have greater prevalence of cardiometabolic risk factors as compared to nondiabetic patients, more severe coronary lesions, less LVEF and more heart failure during hospitalization. Coronary bypass is often indicated in this population.



Submission ID: 742

SUBCLINICAL SYSTOLIC DYSFUNCTION IN BREAST CANCER PATIENTS

Bennour Emna, Rahma Karmous, Ikram Kammoun, Ahmed Sghaier, Lobna Laroussi, Jaweher Arfaoui, Mohamed Amine Boussema, Zaineb Ajra, Afef Ben Halima, Faouzi Added, Sonia Marrakchi, Salem Kachboura

Abderrahmen Mami hospital, Tunisia

Background:

Breast cancer is the first female cancer all over the world and is a public health concern. The survival of breast cancer patients has been improved thanks to the progress accomplished in chemotherapy therapeutics and targeted therapies. However, cardiovascular side effects have increased. Cancer therapeutics-related cardiac dysfunction (CTRCD) is a serious complication of anti-cancer treatment. The aim of our study was to determinate the incidence of subclinical systolic dysfunction, a new entity defined by the European Society of Cardiology (ESC) as a decrease of global longitudinal strain (GLS) by more than 15%.

Methods:

This was a longitudinal, prospective and monocentric study. Eighty female patients diagnosed with breast cancer, receiving anthracycline and/or trastuzumab and addressed to the echocardiography lab of Abdurrahman Mami hospital's cardiology department, were enrolled between 2017 and 2019. A clinical and echocardiographic monitoring were done according to the chemotherapy protocol.

Results:

The mean age of our patients was 49.9 ± 10.8 years. The mean left ventricular ejection fraction (LVEF) was at 64 ± 4.4 %. Our population was divided into three therapeutic groups: 51 patients received anthracycline and trastuzumab, 10 patients received only anthracycline and 19 patients received only trastuzumab. The incidence of subclinical cardiac dysfunction was 25%.

Conclusion:

Echocardiographic monitoring of breast cancer patients should assess the left ventricular systolic function by both Simpson biplane LVEF and GLS. In fact, GLS may allow an early screening of subclinical cardiac dysfunction.

Submission ID: 740

HAS THE PROFILE OF NATIVE INFECTIVE ENDOCARDITIS CHANGED LAST TEN YEARS?

Amine Boussema, Sabrine Soudani, Meriem Drissa

Introduction:

The aim of this study is to outline recent changes in the profile of native infective endocarditis (NIE) in a tertiary care hospital in Tunisia over the last 10 years and to determine predictors of outcome.

Methods:

We gathered retrospectively the Data of 130 patients who fulfilled the modified Duke's criteria for native IE between the period 2007-2019.

The logistic regression model was used to identify predictive factors for death.

Results:

The mean age of patients was 39.2 ± 14 years, a male predominance was noted with a sex ratio of 1.34. The median time

from admission to diagnosis was 15 days. Rheumatic heart disease was the predominant underlying heart condition (92%). The infective agent was identified in 40.9% of cases, the most frequent causative agents were streptococci (46.6%), followed by staphylococci (42.2%). Echocardiography showed vegetations in 90% of cases, abscesses in (12.7%) and valvular mutilation in 21%. Complications were dominated by heart failure in 36% of patients. Surgery was performed during the acute phase of the IE in 29% of cases. The overall in-hospital mortality was 21.8%. On multivariate analysis, staphylococci infection, heart failure, neurological complications and abscesses were predictors of in hospital mortality,

Conclusions:

NIE remains a severe disease affecting the young population in Tunisia, rheumatic heart disease continues to be the most common underlying heart condition, and streptococci were the major causative agents, its prognosis is still dark with high rate of mortality

Submission ID: 724

FACTORS PROLONGING HOSPITAL LENGTH OF STAY IN PATIENTS WITH ACUTE CORONARY SYNDROME

Chenik sarra, Talhaoui Amira, Karima Taamallah, Yassine Jabloun, Haggui abdeddayem, Nadhem hajlaoui, Dhaker Lahidheb, Wafa Fehri

Military hospital of Tunis, Tunisia

Introduction:

Several studies have looked at prognostic impact of cardiovascular risk factors in patients with acute coronary syndrome (ACS). Length of stay is used as an indicator to show the efficacy of hospitals. An increase in hospitalized days decreases the efficacy of hospitals in the other hand. A longer in-hospital stay period, resulting in an increased management cost.

Purpose:

The objective of our study was to investigate the impact of cardiovascular risk factors and concomitant diseases on length of stay in patients with ACS.

Methods:

This was a retrospective and descriptive study of patients with acute coronary syndrome without persistent ST segment elevation who were hospitalized at cardiology department between July 2018 and July 2019.

Results:

Our study included 141 patients of which 76 patients had an angina recurrence and 65 patients had an unstable angina. Regarding the influence of risk factors on length stay, we did not find a significant difference for Diabetes (4 ± 4 VS 4 ± 2 with $p=0.152$), for hypertension (4 ± 4 VS 4 ± 4 with $p=0.426$). However, we found significant prolongation of length stay for males (5 ± 4 VS 3 ± 2 with $p=0.007$), for patients with renal failure (5 ± 4 VS 3 ± 2 with $p=0.001$) the presence of ACS complicated by left ventricular failure (4 ± 3 VS 7 ± 3 with $p=0.05$ and worsening of renal function post coronary angiography (4 ± 2 VS 6 ± 6 with $p=0.01$).

Conclusion:

Patient with prior renal failure and ACS complicated with heart failure and contrast induced nephropathy should be used to identify patients at high risk of prolonged hospitalization, and services should be directed accordingly.

Submission ID: 738

HOW TO MANAGE PATIENTS ON VITAMIN K ANTAGONISTS IN THE COVID-19 ERA

Ahmed SGHAIER, Emna BENNOUR, Ikram KAMMOUN, Rahma KARMOUS, Ali KHORCHANI, Lobna LAROUCI, Jawaher ARFAOUI, Amine BOUSEMMA, Farouk DAOUD, Afef BEN HALIMA, Faouzi ADDED, Sonia MARRAKCHI, Salem KACHBOURA

Abderrahmane Mami Hospital, Tunisia

Introduction:

many healthcare resources have been and continue to be allocated to the management of patients with COVID-19. This pandemic influenced our healthcare system aiming at a minimum of contact between patients and professionals. We tried to study the impact of this disease, on cardiac patients under anticoagulation with vitamin K antagonists (VKA) and to propose an algorithm to facilitate their monitoring.

Materials and method:

This is a retrospective, descriptive study including patients on VKA hospitalized at the Ariana cardiology department or arriving at the outpatient clinic or contacted by telephone during the month of August 2020.

Results:

A total of 100 patients were collected. The average age was 61.59 years old. 58% of the patients did not know their target international normalized ratio (INR). During lockdown period, only 49% of patients monitored their INR. 71.7% of blood samples were taken in a private laboratory and 27.3% in another nearby public structure. To adjust their treatment, 20% of patients called their treating physicians, 31% saw another physician while 49% adjusted the doses on their own. After reopening, 54% of patients did not visit the hospital for one month. At the time of the first medical contact, 57% of the INRs were in the therapeutic zone. There is a significant relationship between therapeutic education and the regularity of the INR control in lockdown ($p = 0.01$) and between the regularity of the INR monitoring and an INR after lockdown in a therapeutic zone ($p = 0.000$). In the light of our results, we proposed an algorithm for the management of anticoagulant therapy in uninfected patients.

Conclusion:

The need to observe social distancing or lockdown rules should not affect the quality and safety of anticoagulant therapy. Therefore, we strongly urge clinicians to ensure patients receiving VKA therapy are appropriately managed despite the COVID-19 crisis.

Submission ID: 727

CONTRIBUTION OF THE CARDIAC COMPUTED TOMOGRAPHY IN THE EXPLORATION OF MECHANICAL VALVE PROSTHESIS

Mouna Bousnina, Amine Jemel, Tarek Sendi, Khedija Soumer, Adel Mrad, Chaker Jaber, Adel Marghli

Abderrahmen Mami Hospital, Tunisia

Background:

Cardiac ultrasound (US) is considered the gold standard for exploring complications of prosthetic valves. However, it is limited by the presence of artifacts generated by the prosthesis and is limited in the exploration of the peri-valvular environment. The cardiac computed tomography (CT) is an examination that overcomes these insufficiencies. The objective of our work was to describe and illustrate the complications of mechanical valve prostheses identified by cardiac CT, and to assess its concordance with the cardiac US.

Methods:

This was a descriptive, retrospective study including patients with suspected valve prosthesis dysfunction on ultrasound and having been jointly explored by a cardiac CT at the medical imaging department in Abderrahmen Mami hospital in the Ariana between March 2018 and March 2019.

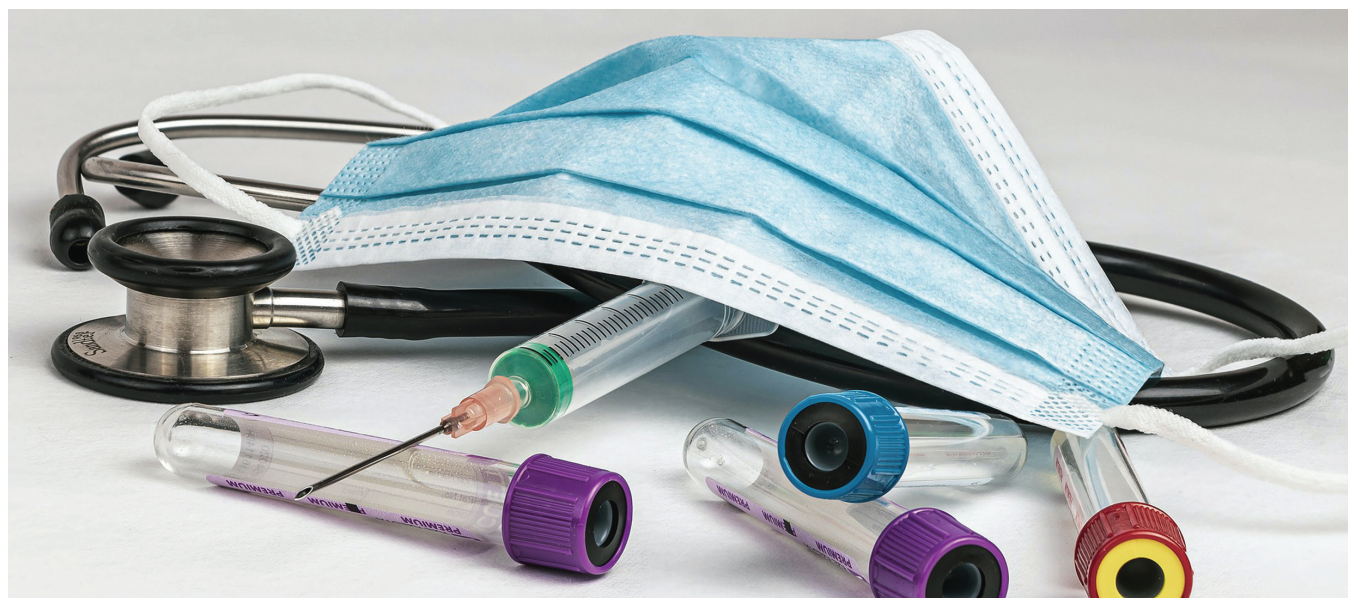Results:

The study included 22 patients (12 women and 10 men with a mean age of 57 years) with 27 prostheses: 20 aortic and 7 mitral. On CT, Pannus was observed on aortic and two mitral prostheses, still located on the ventricular side of the prostheses. The thrombus was identified in six patients with aortic prostheses. No correlation was found between the different parameters of the prostheses and the dilatation of the ascending aorta.

Subvalvular aortic stenosis was significantly correlated with the thickening of the basal interventricular septum ($p=0.037$). The opening angle of one or both leaflets was less than 80° in 19 patients. One or both leaflets were blocked in closing position in 3 patients. CT was more efficient for the diagnosis of a prosthetic mobility defect with a statistically significant difference $p=0.009$. The presence of a defective opening of the aortic prosthesis discs was significantly associated with an increase in the Trans prosthetic gradient at US ($p=0.047$).

Conclusion:

Cardiac CT is a reliable complementary tool for the exploration of mechanical valve prostheses.



Submission ID: 744

URGENT SURGICAL REMOVAL OF A RUPTURED INTRACARDIAC CYST MIMICKING A SEPTAL CARDIAC TUMOR WITH NEUROLOGICAL SYMPTOMS

TESNIM BESBES, BILEL DERBEL, SOBHI MLEYHI, MALEK BEN MRAD, MOHAMED MESSAI, JALEL ZIADI, RAOUF DENGUIR

Department of cardiovascular surgery Rabta University Hospital
Tunis Tunisia

Introduction:

Cardiac echinococcosis is a rare disease, involving almost any part of the heart, but frequently in ventricular myocardium. Acute stroke as a presenting symptom of cardiac hydatid disease is exceptionally rare, and only a few cases have been reported in the literature.

Case:

We represent the case of a 37 year old man with unknown medical history who was admitted in the neurology department for exploration of acute blurred vision. Initial physical examination revealed isolated fever at 39.5°C with no other abnormalities. Electrocardiography showed negative T waves in the inferior territory and hyperleukocytosis along with elevated C reactive protein were found in the biology analysis. A complementary cerebral CT scan revealed signs of recent ischemic stroke in the territory of the left posterior cerebral artery. A systematic transthoracic echocardiography was performed and showed an anechoic mass measuring 31* 33 mm in diameter in the interventricular septum protruding and ruptured in the left ventricular chamber. A thoraco-abdomino-pelvic CT scan confirmed an isolated round cystlike structure involving the septum and evoking hydatid cyst type according to the Gharbi Classification. As the patient is of a North African country the diagnosis of cardiac echinococcus was most likely. The patient was then transferred to the cardiovascular surgery department for urgent surgical treatment. With median sternotomy and under cardiopulmonary bypass a puncture and evacuation of the cyst content, sterilization of the cavity with scolicedal agents (hypertonic solution) and excision of the endocyst along with the ectocyst were performed. After excision of the cyst, the residual cavity was plicated (capitonnage) with continuous Prolene sutures. Sponges soaked in hypertonic saline were distributed, to prevent local dissemination, throughout the pericardial cavity. Post operative course was uneventful and patient was discharged home under albendazole therapy (400 mg twice daily) for 12 weeks postoperatively.

Conclusion:

Cardiac echinococcosis is an extremely rare disease with echocardiography and cardiac CT imaging being considered diagnostic modalities of choice. Differential diagnosis should include cardiac tumours, thrombus, myxoma and sarcoma.

Submission ID: 757

ROLE OF MULTIMODALITY IMAGING IN THE ASSESSMENT OF PROSTHETIC HEART VALVE OBSTRUCTION

Rahma Karmous, Bennour Emna, Ikram Kammoun, Jaweher Arfaoui, Mouna Bousnina, Ahmed Sghaier, Lobna Laroussi, Henda Neji, Monia Attia, Saoussen Hantous, Meriem Affes, Ali Khorchani, Farouk Daoud, Salem Kachboura

Abderrahmen Mami hospital, Tunisia

Background:

In patients with suspected prosthetic heart valve (PHV) dysfunction, routine evaluation transthoracic and transesophageal echocardiography are considered as the first line imaging but may provide unsatisfactory results related to reverberations and acoustic shadowing. This study assessed the value of ECG-gated multidetector computed tomography (MDCT) imaging as a complementary imaging modality in suspected prosthetic obstruction for diagnosing its cause.

Methods:

Patients with suspected PHV obstruction were prospectively recruited between 2018 and 2020 in the cardiology Departement of Abderrahmen Mami hospital.

All patients underwent routine diagnostic work-up (transthoracic and transesophageal echocardiography) and additional MDCT imaging. We compared the diagnosis based on echocardiography and on MDCT information.

Results:

Our study enrolled 23 patients. The median age was 52.5 ± 14.2 years (26-78). Sex-ratio was 0.5.

12 patients had an aortic prosthetic valve, 4 patients had a mitral prosthetic valve, 6 patients had mitral and aortic prosthetic valves and only one patient had a tricuspid bioprosthetic valve.

The etiology of this obstruction was: a thrombus in 12 cases, a pannus in 4 cases, a mismatch in 2 cases and a reduction in a leaflet motion in 3 cases, a vegetation in one case and a bioprosthetic degeneration in one case.

Ultrasound imaging and MDCT found same results for mismatch and bioprosthetic valves. Echocardiogram was more performant in the diagnosis of thrombus (p = 0,02). The addition of MDCT showed incremental value to routine evaluation for detecting pannus (p = 0,02) and leaflet motion.

The leaflet restriction diagnosed by MDCT was significantly associated with a thrombus (p = 0,03).

Conclusion:

A multimodal imaging assessment including ultrasound imaging and CT is complementary to diagnose PHV obstruction. MDCT imaging modality was valuable in the majority of patients with suspected PHV obstruction, mainly for detecting the pannus and for leaflet motion.

Submission ID: 747

SHOULD WE ALWAYS CRUSH?

Mohamed Aymen Ben Abdesslem, Zied ben Ameer, Fekih Ahmed, Wassim Saoudi, Imen Bouhlel, Hatem Bouraoui, Abdallah Mahdhaoui, Samia Ernez, Gouider Jeridi

Farhat Hached university Hospital, Cardiology Department. Research Laboratory LR14ES05 Faculty of Medicine of Sousse University of Sousse

Case presentation:

a 65 male, active smoker, presented in 2017 with an anterior ST elevation myocardial infarction complicated with ventricular fibrillation and cardiogenic shock. Primary PCI was performed with a 3 mm x 33mm drug eluting stent from left main to left anterior descending. Patient was discharged at day 15 after 48 hours on mechanical ventilation and inotropic drugs. On October 12th, 2020 presented with an NSTEMI complicated with cardiogenic shock ECG showed an ST depression in anterior and inferior leads. Angiography showed a proliferative in stent restenosis in distal LM evolving ostial left circumflex with impaired TIMI flow. The LM bifurcation angle was wide. Our strategy was an upfront 2 stents implantation securing access to LCX first. Techniques discussed were DK crush and reverse TAP and the latter was chosen. This choice was motivated first, by the wide angle of the bifurcation. Second it was easier and less cumbersome technique. Finally, in this particular case, DK crush will lead to four layers of metal in the left main. Steps were wiring both branches, positioning the first stent in the LCX with minimal protrusion, after deploying the first stent, a first kissing balloon was done, the wire in the LCX was withdrawn then the second stent was deployed from LM to LAD across LCX ostium. After rewiring the LCX a second kissing balloon was done. In this particular case due to the short, stented distance before the carina, proximal optimization technique wasn't possible. A good final result was achieved. Patient was finally discharged at day seven.

Learning points:

although data support DK crush technique in complex distal left main bifurcation, this technique is not mandatory in all scenarios. In urgent situation with poor haemodynamic status and appropriate bifurcation angle, simpler techniques should be preferred.

Submission ID: 752

OSTIAL RCA IN-STENT RESTENOSIS AND ANOMALOUS LEFT MAIN ORIGINATING FROM THE RIGHT CORONARY CUSP TREATED WITH SZABO TECHNIQUE

Mohamed Aymen Ben Abdesslem, Zied Ben Ameer, Wassim Saoudi, Imen Bouhlel, Hatem Bouraoui, Abdallah Mahdhaoui, Samia Ernez, Gouider Jeridi

Farhat Hached University Hospital Sousse. Research Laboratory LR14ES05 Faculty of Medicine of Sousse University of Sousse, Tunisia

A 63-year-old female, with diabetes mellitus, hypertension, a history of coronary artery disease, previous stent of the right coronary artery (RCA) and an anomalous origin of left main from the right sinus of Valsalva, presented with unstable angina. She underwent diagnostic angiography via the right femoral artery. A 90% in-stent restenosis of the ostial RCA was found as well as an estimated 60% restenosis in the mid RCA. Geographical miss attested by the clear stent images from the ostium was the mechanism of the stent failure.

A second insufficient coverage of the ostium and an excessive protrusion in the aorta with the risk of complicating further access

to both RCA and left main has to be avoided. Szabo technique was chosen to achieve a precise positioning of the new drug eluting stent (DES), and to avoid the above complications.

The technique was first described by Szabo et al in 2005 and involves a second guide wire placed in the aorta (or branch vessel for a non aorto-ostial lesion) to anchor the stent. The stent is prepared by a low pressure inflation (2 atmospheres) with the protective sleeve left in place while exposing the proximal struts. The remainder of the stent is compressed with the sleeve. The wire is passed through the proximal strut of the stent followed by crimping of the "lifted" strut; however, not to the degree that the anchor wire is not mobile. The stent then travels over the primary guide wire and the anchor wire, which stops forward motion of the stent at the vessel ostium (slides). The stent is then deployed at low or nominal pressure, followed by removal of the anchor wire.

Caution must be used when applying this technique. Intravascular ultrasound follow-up has demonstrated stent protrusion and distortion, which may be more a concern in non aorto-ostial lesions. In addition, there is the potential for stent dislodgement as a result of stent manipulation. While the Szabo technique is not without limitations, it seems to provide complete ostial coverage for aorto-ostial lesions

Submission ID: 748

FULMINANT MYOCARDITIS IN A PATIENT WITH SEVERE ACUTE RESPIRATORY SYNDROME CORONAVIRUS 2

SANA KHARRAT, SALMA JERBI, Saba Makni, Malek Hafdhi, Mabrouk Bahloul, Mounir Bouaziz

INTENSIVE CARE, Tunisia

The COVID-19 pandemic has raised awareness of certain conditions that may be caused by an infection with SARS-CoV-2, the virus that causes COVID-19. In addition to acute respiratory distress syndrome (ARDS), there is a range of multi-organ dysfunction complications including cardiovascular disorders. Although cardiovascular complications have been widely described, myocarditis was rarely reported.

To describe the presentation of acute myocardial inflammation in a patient affected by coronavirus 2019 (COVID-19) we report the case of a 35-year-old woman without previous history of cardiovascular disease who developed a respiratory distress a week after upper respiratory tract symptoms. She was confirmed having COVID-19 by polymerase chain reaction (PCR) 6 days earlier and recovered from the influenza-like syndrome.

On exam she had severe hypoxia, bilateral crepitation on auscultation, requiring emergent intubation. She also presented signs of right-sided heart failure, including raised jugular venous pressure and peripheral edema. Chest x-ray showed diffuse bilateral interstitial opacities and minor pleural effusion on the left.

Electrocardiogram showed features of myopericarditis. Echocardiogram revealed global hypokinesis with severely reduced systolic function, an ejection fraction of 30%, without valvular heart disease.

Blood test results showed elevated levels of inflammatory markers, including C-reactive protein and procalcitonin and high levels of cardiac enzymes both Troponin and BNP. Based on prior investigations other cardiovascular disorders were eliminated.

The patient's ventilator settings were placed with high positive end-expiratory pressures and low tidal volumes; She then developed shock and was placed on norepinephrine, dobutamine and furosemide leading to resolution of the critical state and a stability of her vital signs.

The importance of this case lies in highlighting the severe cardiac involvement in a young patient, without previous risk factors, positive for COVID-19 and the favourable response to the medical treatment given.

Submission ID: 758

SEVERE SCORPION ENVENOMATION IN CHILDREN AND CARDIOVASCULAR TROPISM

SANA KHARRAT

INTENSIVE CARE, Tunisia

The severity of scorpion envenomation essentially consists on left heart dysfunction with pulmonary edema and / or shock. Adrenergic myocarditis, toxic myocarditis and myocardial ischemia are the main mechanisms. Objective The aim of the study is to describe the cardiac manifestations observed during serious scorpion envenomation's in children. Patients and

Methods:

This is a retrospective study of all children with severe scorpion envenomation by analysing clinical, biological, electrical and cardiographic cardiovascular manifestations.

Results:

A total of 10 patients were admitted with severe scorpion envenomation; between 2017 and 2018. Cardiac involvement is present in 9 cases. Tachycardia is objectified in 9 patients. High blood pressure is present in 4 cases, vascular collapse in 3 cases and acute pulmonary edema is found in 5 cases. Myocardial ischemia is found in 80% of envenomed patients.

Conclusion:

Our work confirms that cardiac involvement is frequent and severe during scorpion envenomation in children.

Submission ID: 753

ANALYSIS OF RIGHT VENTRICULAR FUNCTION BY 2D SPECKLE IMAGING IN PATIENTS WITH ACUTE MYOCARDIAL INFARCTION

Mahfoudhi H, Taamallah K, Jabloun Y, Chenik S, Chourabi C, Haggui A, Hajloui N, Lahidheb D, Fehri W

Cardiology Departement, Military Hospital of Tunis, Tunisia

Right ventricular (RV) myocardial strain is a new useful tool to evaluate RV function. The aim of our study was to use 2D speckle imaging (2DSI) on the walls of the RV to derive regional and global RV function and to study the clinical value of these parameters in patients with first-time acute myocardial infarction (AMI).

Methods:

We analysed 50 patients admitted with AMI treated with primary percutaneous coronary intervention. We compared them to 50 healthy patients. Complete echocardiography was performed between two and four days after admission. To assess RV function, we analysed the two walls of the RV: septal and lateral from 4 C view.

We measured maximal systolic strain (%) in the basal, median and apical segments of these two walls by 2DSI. We calculated lateral and septal strain as the means of three segments of respectively lateral and septal walls and global RV strain as the mean of these 6 values. We also measured TAPSE and maximal

velocity of systolic wave (S max) on the lateral tricuspid annulus using Doppler tissue imaging.

Results:

The average age of our patients is 62 +/- 12 years. The overall RV strain is 19.70 ± 5.45. strain correlate well with the values of TAPSE and S max (p <0.01).

All the strain and TAPSE values are significantly higher in the controls (respectively p = 0.001; p = 0.02). The alteration of the overall RV strain in patients with a anterior MI is mainly due to the significant decrease in the septal strain. The overall RV strain and especially the lateral RV strain are significantly more altered during inferior IDMs compared to anterior IDMs (p = 0.001 and p = 0.003, respectively)

Conclusion:

2DSI allows the calculation of RV global strain which is well correlated to standard echocardiographic parameters of RV function. Furthermore, study of regional and global RV strain adds interesting information in the evaluation of RV dysfunction in patients with AMI.

Submission ID: 743

CHALLENGING ENDOVASCULAR TREATMENT OF THROMBOSED ARTERIOVENOUS DIALYSIS FISTULA.

Aloui W, Miri R, Mleyhi S, Ben Abdeltif B, Derbel B, Ben Mrad M, Denguir R

Cardiovascular surgery department Rabta Tunis Hospital, Tunisia

Introduction:

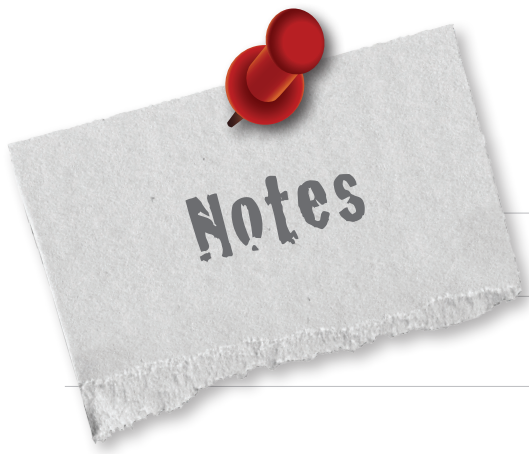Functional vascular access is essential for adequate hemodialysis treatment in patients with end-stage renal disease. Autogenous arteriovenous fistula are superior to central venous catheters or grafts. Fistula thrombosis is a frequent complication and may lead to the loss of vascular access. The fistula salvaging is challenging in vascular surgical practice, especially when using an endovascular approach.

Case:

We report a woman (age 63) with diabetes and end-stage renal disease for 9 years who had a thrombosed radial fistula and a functional humero-cephalic fistula created 6 months ago. She reported arm pain during dialysis, decreased flow and high venous pressure in extracorporeal circulation. The diagnosis of thrombosis of the left terminal cephalic vein over 13 cm with development of venous collaterals was confirmed by ultrasound and fistulography. A venous angioplasty was performed with immediate excellent result, and the fistula remained patent and functional during the 6 months of follow-up.

Conclusion:

Several studies have reported that the outcome of endovascular and surgical treatment for thrombosed vascular access is comparable with less morbidity in endovascular treatment. Indeed, the endovascular approach extends the lifespan of the fistula and does not exclude the possibility of surgery. However, endovascular procedures require sophisticated equipment and highly trained teams

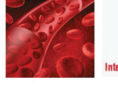


Notes

See you in




PAFCIC 2021



Cardiology A Department - PAFCIC Secretariat ; Fattouma Bourguiba University Hospital

Phone: +216 73 106 000 - Mobile : +216 98 525 759 - Email: secretariat@pafcic.org

logistics :  millesima events +216 23 99 44 98 - pm4@millesima-events.com

